

## LAB LINES

Diagnostic news and trends from the Colorado State University Veterinary Diagnostic Laboratories  
Volume 22, Number 2  
Fall/Winter 2017

Meet the Lab

## New Anatomic Pathologist Magunda a Specialist in Arthropod-Borne Disease


To new Anatomic Pathologist Forgivemore Magunda, joining the CSU Veterinary Diagnostic Lab diagnosticians and researchers was his longtime goal. Not only do the personnel and institution epitomize excellence in veterinary education, diagnostics and research, he says, but also they are particularly strong in his “fields of passion:” Veterinary pathology, microbiology and immunology.

Magunda’s journey to Fort Collins started following completion of a Bachelor of Veterinary Science, the equivalent of a U.S. DVM, at the University of Zimbabwe.

“I had heard wonderful things about the caliber of veterinary medicine in the USA in general,” he says, “and its amazing integration with research at the CSU College of Veterinary Medicine and Biomedical Sciences, in particular. As a young veterinarian in Zimbabwe, I was determined to come to the USA to learn and contribute.”

Sensing he needed experience to be competitive for one

Meet the Lab



of the VDL’s highly coveted pathology positions, Magunda joined a high-quality mixed-animal practice, volunteered

**See MAGUNDA, page 3**

## New Pathologist Juan Muñoz: Bringing Further Perspective to VDL

With training that spans the hemisphere, experience with multiple species and an emphasis on exotics, wildlife and teaching hospital cases, new VDL Anatomic Pathologist Juan Muñoz looks forward to contributing even more depth to CSU VDL’s offering to clients, veterinary students and the scientific community.

Muñoz grew up in Mexico City and received his MVZ, that country’s DVM equivalent, from the National Autonomous University of Mexico in 2009. That year, he did a diagnostic externship at Northwest ZooPath, in Monroe, Wash., supervised by founder and internationally recognized authority in non-domestic-species pathology Michael Garner. His pathology residency and PhD work following from 2009 to 2015 at Washington State’s diagnostic lab. After obtaining his board certification in anatomic pathology in 2015, Muñoz worked for two years as assistant professor and anatomic pathologist at Wyoming’s state lab.



“I’m excited to come back to a strong pathology residency program at CSU,” he says, “to get the opportunity

**See MUÑOZ, page 4**

## Diagnostic Sample Quality Assurance

# Packing and Shipping Histopathology Samples for Successful Trimming

—Katherine Luntsford, CSU VDL Technician

Here at the CSU Diagnostic Lab, our tissue trimming section consists of three trimming technicians and a few students, who trim all biopsies from veterinary hospitals outside the teaching hospital. This team can trim up to 200 cases daily—sometimes more—from all around the world, ranging from endoscopic biopsies to spleens to full limbs. We trim these biopsies into cassettes that may include a nickel-sized tumor sample with margins, or smaller endoscopic, wedge or needle biopsy samples. These are then processed overnight, embedded in paraffin, sectioned and stained in the formation of glass slides for the pathologist to read.

What can you do when submitting a biopsy to help that team make the most of your sample?

## SHIPPING YOUR SAMPLE

Shipping formalin can always be a bit difficult. Send your sample with enough formalin to fix the tissue, but not so much as to cause an issue with your shipping service in case of leak. If you don't have enough formalin, we are happy to fix the tissue here at no extra cost. Make sure all fresh samples are sent over night. Larger samples can also be wrapped in formalin soaked paper towels or puppy pads and then double bagged, to begin the fixation process. We will then add more formalin to the sample as soon as we receive it to complete fixation.

Formalin will make fresh tissue harden. Always send your tissue in a container with a mouth as wide as its

base, to ensure we are able to safely retrieve the tissue. Please refrain from sending glass containers. They are easily broken and can make it difficult to get larger tissues out of the jar once formalin causes hardening.

Any tissue that is dried on a tongue depressor or paper will come off that surface once it has been soaked in formalin. If the tissue manages to stay on that surface, there is a risk that the tissue will peel up particulates which could interfere with the diagnosis. If your submitted tissues need to be kept separate, please use separate jars for each. We can also happily provide tissue cassettes to your clinic for use in tissue IDs. We can also provide small screen inserts for endoscopic biopsies.

Please use a wax tape to seal your jars. Plan ahead for leaks, and add appropriate absorbent material, such as deformalizing pads, puppy pads or newspaper. Any cloth or paper material is ideal.

Always make sure your submission form is kept in a separate bag, in case fluid does leak. It's a good idea to keep a copy of the form at your clinic, just in case questions arise regarding the sample.

If you have any further questions about packing and shipping tissue, please feel free to call the Tissue Trimming lab directly, at (970) 297-4505. We are also happy to help you come up with an estimate if your client has financial concerns.

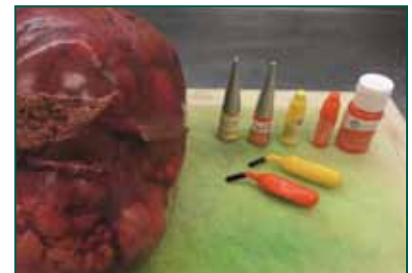**Our \$59 charge includes three slides to be read out by the pathologist. Any additional slides are an extra \$10 each. If you or your client have financial limitations or concerns, please include this fact in the history section of the submission form. We are happy to abide by these limitations.**

## Managing Surgical Margins

When tumor samples arrive in the laboratory after being in formalin and losing their natural color, it can be very difficult for us to determine the surgical margin unless it is marked. Keep these tips in mind:

- If directional surgical margins are needed, please use either suture or staples to denote the directional margins. For example, use one suture to indicate medial; two sutures, lateral, and so on.
- Please do not define margins with the brand of suture or type of knot.
- Ensure these margin indications are detailed in the history section of the submission form.

- Inking is also a reasonable way to mark surgical margins on your tissue. Ink will survive processing and be clearly evident on the histologic slides. Ink can be purchased through various medical supply agencies and histology-specific companies.
- When inking margins on a sample, the tissue needs to be dry to apply ink. After application, the tissue will need to be dried again for at least five minutes before placing in formalin.
- For more on inking margins, see *LabLines*. 2015 Fall/Winter;20(2):3.



Tissue-marking inks (above) will maintain margin indications through shipping and processing (right).



**How will your tissue sample be trimmed?**

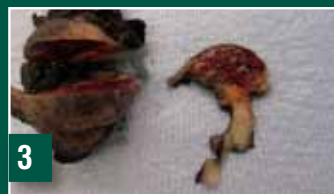All tissues sent to the VDL for histopathology, no matter the size or tissue, will be trimmed into a cassette that holds a nickel-sized piece of tissue (excluding endoscopic biopsies). Our job is not only to include the margin for microscopic measurements and mass identification, but also to make sure all tissues are trimmed for proper histology lab processing. Once tissues are trimmed, the cassettes are processed through an overnight cycle of various alcohols and treatments to remove all formalin. Next, the technicians embed the tissue in a thick block of paraffin. Once the block has cooled, it is cut into thin ribbons which are then placed on a glass slide and then stained to produce slides for the pathologist to read. Quality control directly affects the diagnosis. If our trimming technique were not correct and the tissue too large, the paraffin would not completely surround the tissue and risk the tissue not staying in the paraffin block. Our trimming process also affects what the pathologist sees. If the tissue were to be trimmed too thick, the formalin could not be fully removed, producing a poor slide.



**1** The mass is fixed for 24 hours, and the surgical margins inked black.



**2** The first cut made is across the narrowest point, through the entire sample.



**3** The cut tissue is divided from the mass.



**4** Each side margin is then taken to include mass and a measurable margin—the tissue at the bottom of the picture above is the deep margin.



**5** The margin is then trimmed on one half of the entire mass, now that it is halved and margins taken from sides and deep. In this case, the tissue has been cut longitudinally, and the margin from that end placed in a cassette.



**6** The other half from the first cut is now trimmed similarly.



**7** The tissue is cut longitudinally (above) and trimmed to fit a cassette (below).



**8**

**MAGUNDA**

(Continued from page 1)

on rabies prevention and spay/neuter clinics and did locums at the national equine race-course. That exposure to general practice gave him a keen perspective into client and clinic needs in diagnostics and research. He also gained experience in field epidemiological surveillance and management of notifiable/exotic diseases during outbreaks.

He then leveraged that experience to get into the veterinary emphasis of the master of public health program at the University of Missouri, where he was a volunteer house officer in the agriculture animal medicine and surgery service. He continued as a food-animal medicine and surgery clinician at Washington State University, where he transitioned into his ini-

tial passion—a combined doctorate in immunology, molecular biology and infectious disease and anatomic pathology. Since then, his work has included pathology service and teaching and research into the immunology and molecular mechanisms of arthropod-borne diseases. Research interests have included human and animal anaplasmosis, lyme disease, neoplastic disease and aquatic diseases.

Magunda's passion is to apply pathology and research to improve clinical outcomes—both animal and human. In particular, he's looking at molecular and immunological mechanisms of diseases like anaplasmosis, malaria, tuberculosis and Zika. ▲



Diagnostic Sample Quality Assurance

# Pro Tips on Urine Culture



— Josh Daniels, DVM PhD, DACVM, Bacteriology Section Head

**FOR MORE INFORMATION**

1 Recent companion animal urinary tract infection guidance: [www.iscaid.org/wp-content/uploads/2013/10/Urinary-guidelines.pdf](http://www.iscaid.org/wp-content/uploads/2013/10/Urinary-guidelines.pdf).

Microbiological culture of urine from companion animals is one of the most common tests performed in the bacteriology lab. Among the many indications for submission of urine for culture are:

- Lower urinary signs
- Pyelonephritis
- Prostatitis
- Fever of unknown origin
- Radiographic detection of cystic calculi.

Some practitioners also like to screen animals for occult UTI; however, this practice is becoming less common, given the most current recommendations for management of asymptomatic bacteriuria.<sup>1</sup>

For the most accurate results, we recommend the following for submission of urine samples:

1 Whenever possible, collect samples via antepubic centesis (cystocentesis) using a needle just long enough to reach the bladder. If an overly long needle is used, such as a 1.5-inch needle on a miniature Dachshund, the needle may occasionally penetrate the dorsal wall of the bladder and enter the colon, leading to aspiration of colonic material and likely contaminated cultures. The risk of this adverse event is greater when the bladder is not distended and the patient is hard to control.

2 Once a sample is obtained, reserve at least 1 mL for culture in a plain sterile container, such as a “red-top” tube. Do not use EDTA tubes, as EDTA is bacteriostatic to gram-negative bacteria. Urine should be stored in the refrigerator within 30 minutes of collection if not processed immediately, and transported to the laboratory chilled, but not frozen, within 24 hours.

3 The overwhelming majority of uropathogens are not fastidious; therefore, practitioners don’t need

to plate samples in-house prior to shipment to the laboratory for fear of decreased sample viability. Some practitioners like to screen urine themselves in-house, using plated media or Uricult-type devices, and only send samples with growth to the laboratory for bacterial identification and antimicrobial susceptibility testing. If you do prefer that approach, be aware that it can delay turnaround-time, and it also has the potential to miss cultivation of rare uropathogens that require special incubation conditions, such as *Mycoplasma* spp. and *Corynebacterium urealyticum*.

4 Finally, always submit a concurrent sample for urinalysis, or perform it in-house, to aid interpretation of microbiological culture. ▲

**SUBMISSION GUIDELINES FOR SUCCESS**

**Urine Cultures**

- Submit at least 1 ml in sterile container
- Refrigerate, unless using port-a-cul for transport media
- Submission deadline 4:30 p.m. weekdays, noon weekends
- Allow three to five days turnaround

**MUÑOZ**  
(Continued from page 1)

to interact with veterinary students and pathology residents on the necropsy floor.

“One of the realities of working in the diagnostic laboratory setting is that, of course, we don’t always get a definitive diagnosis in all cases,” he says. “But my attitude is that a lack of diagnosis is not necessarily a loss. It can actually offer a great opportunity to explore. I like to use my cases when possible to try to do some research surrounding those questions they raise.”

Muñoz’ special interest in infectious diseases, wild-

life and exotic disease, dermatopathology, oncologic pathology and prion diseases fits well with CSU VDL’s continuing emphasis on next-generation diagnostics.

“I definitely see that as a good opportunity. I like to use my cases to go the extra mile, to use that new and innovative technology in the diagnostic repertoire to investigate possible new and emerging diseases.”

Muñoz will be involved in residency training, necropsy work, reading slides, consulting and providing diagnostic suggestions, along with some guest lecturing. ▲



## Advances in Molecular Diagnostics

# Novel Tools to ‘Search the Haystack’

Polymicrobial diseases, those pathologies induced by multiple microorganisms acting together or in sequence to contribute to disease complexes, continue to confound veterinary diagnosis and treatment.

Two notorious examples in food-animal medicine are bovine respiratory disease complex and bovine abortion. Researchers have recently proposed all manner of diagnostic innovations—lung biopsy, ultrasound, RFID-associated thermography, breath biomarkers, serum haptoglobin, rumen temperature boluses and more—and still BRDC continues to account for an estimated 70% to 80% of all feedlot morbidity and 40% to 50% of all mortality. The polymicrobial nature of bovine abortion similarly confounds diagnosis: During the previous two fiscal years, for instance, the cause of only 42% of bovine cases in the CSU VDL could be determined—for horses, the number falls to 35%; for goats, just 24%.

Obviously, we need novel approaches to clarify the mechanisms behind pathogenesis and to prevent and treat both these two challenging disorders and other polymicrobial complexes.

### INNOVATIVE APPROACHES

One such novel approach is underway here at the CSU VDL. Working with Mark Stenglein, assistant professor in CSU’s Microbiology, Immunology and Pathology department, and MIP research associate Justin Lee, VDL Virology Section Head Christie Mayo has been studying the use of next-generation DNA sequencing to refine polymicrobial complex diagnostics.

Mayo’s work earned a grant award for innovation at October’s annual meeting of the American Association of Veterinary Laboratory Diagnosticians in San Diego. AAVLD and Thermo Fisher Scientific awarded Mayo’s work one of its Innovation in Veterinary Diagnostic Medicine Grant Program awards, based on innovativeness, potential for broad impact on veterinary diagnostic medicine, quality of the science and other criteria.

The aim of the CSU team’s work is to develop a

— Christie Mayo, DVM, PhD, CSU VDL Virology Section Head

novel molecular method based on next-generation sequencing to systematically investigate BRDC and bovine abortion.

### INVESTIGATING THE COMPLEXES’ MICROBIOME

Mayo’s work involves use of the Clustered Regularly Interspaced Short Palindromic Repeats, or “CRISPR” mechanism. A natural component of prokaryotic cells that contains a Cas protein, CRISPR is a gene-editing mechanism able to locate and snip specific parts of the genome and replace sequences with others.

CRISPR has revolutionized the work of many scientists in various disciplines, including Mayo’s. Although much of the work remains in the proof-of-concept stage, applying CRISPR to high-throughput sequencing of all microbial DNA in a specific environment—in the case of BRDC and bovine abortion, the respiratory and reproductive tracts, respectively—could similarly revolutionize diagnostics confounded by the limitations of diagnosing polymicrobial disease by often painstakingly slow conventional pathogen ID tools.

“We’re searching for a needle in a haystack by eliminating the hay to search for the needle,” Mayo told the *Rocky Mountain Collegian* in November. “In diagnostics, it’s not just time and money, but actual life. If we spend too much time looking at the hay, we won’t see what’s causing the problem.”

That type of quick study of the entire microbiome of polymicrobial disease promises not only to cut the time it takes for a causative pathogen to be found, but also to lend insights into the genetics of the pathogens that can make tailored treatment possible and practical. The ability to immediately identify and quantify specific resistance genes, for example, could target antimicrobial therapy around resistance that currently complicates BRDC therapy.

“This is a fundamental and groundbreaking discovery,” Lee told the *Rocky Mountain Collegian*. ▲



CSU VDL Virology Section Head Christie Mayo (left) received one of Thermo Fisher Scientific’s Veterinary Diagnostic Medicine Grant Program awards at this year’s annual AAVLD meeting in October in San Diego.

## CSU VDL in the Field: Case Study

# Paracoccidiomycosis ceti in an Atlantic Bottlenose Dolphin

An adult male Atlantic bottlenose dolphin (*Tursiops truncatus*) found stranded and freshly dead on the beach at Biscayne Bay, Fla., was brought to the attention of the Harbor Branch Oceanographic Institute. An organization within Florida Atlantic University, the institute is a multifaceted program of oceanographic research and monitoring, covering all aspects of marine health from ecology to epidemiology, with particular interest in marine mammal health. Institute biologists and veterinarians respond to strandings along the Florida Atlantic coast, with necropsies performed by veterinarians and staff at its laboratory. The institute submits its histopathology to the zoo/exotic pathology service at CSU's VDL. Through extensive examination of stranding deaths and detailed studies of live populations, the institute has documented multiple common and emerging conditions in wild marine mammals on the Atlantic coast over the last several decades.

## NOVEL YEAST INFECTION

The dolphin in this case was in relatively good body condition, with adequate blubber and normal muscling. Multifocal and coalescing raised, firm, white, 5-mm to 6-cm nodular lesions were identified on the cranial aspect of the rostrum and mandible, the anterior edge of both pectoral fins and the dorsal fin, the dorsum adjacent to the blowhole, the left and right peduncle, and ventral and dorsal fluke. Nodules formed large proliferative plaques up to 60 cm wide, with a prominent central region of hypopigmentation and ulceration.

Histopathology of fluke and peduncle lesions included epidermis varying from acanthotic to ulcerated, with marked expansion of the dermis and subcutis by loose fibroplasia and marked inflammation comprised of

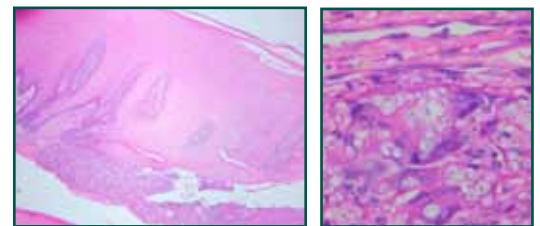
— Sushan Han, DVM, PhD, DACVP, CSU VDL Pathologist; Adam Schaefer, MPH, Epidemiologist, Florida Atlantic University Harbor Branch Oceanographic Institute; Wendy Marks, Biological Scientist, Florida Atlantic University Harbor Branch Oceanographic Institute; John Reif, DVM, MSc, CSU Department of Environmental and Radiological Health Sciences Professor; and Terry Spraker, DVM, PhD, DACVP, CSU VDL Pathologist

large numbers of macrophages, multinucleate giant cells and scattered neutrophils, lymphocytes and plasma cells admixed with abundant edema and mucinous material.

Myriad yeasts of 5  $\mu$ m to 10  $\mu$ m in diameter with a thick, double, refractile wall and clear cytoplasm were embedded throughout the lesions and showed structure consistent with novel *Paracoccidioides brasiliensis* infection and a condition now called paracoccidioides ceti.

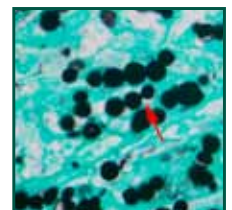
## DEFINITIVE DIAGNOSIS VIA PCR OR IHC

Paracoccidioides ceti in Atlantic Bottlenose Dolphins is caused by chronic infection with an intracellular yeast recently classified as a novel, uncultivable *Paracoccidioides brasiliensis*.<sup>4,10,13</sup> Previously known as lobomycosis or lacaziasis, it has recently been renamed to reflect PCR identification of the causative agent.<sup>13</sup> *P. brasiliensis* is a dimorphic fungus of the order Onygenales, which includes *Lacazia loboi*, *Coccidioides immitis*, *Blastomyces dermatitidis* and *Histoplasma capsulatum*. A related



Histology (clockwise, from above):

- Inflammation was characterized by large numbers of macrophages, multinucleate giant cells and scattered neutrophils, lymphocytes and plasma cells admixed with abundant edema and mucinous material.



- Myriad yeasts of 5  $\mu$ m to 10  $\mu$ m diameter with thick, double, refractile walls and clear cytoplasm embedded in the lesions.
- Yeasts arranged in short chains interconnected by small tube-like bridges were consistent with novel *P. brasiliensis*.

## REFERENCES

- 1 Azevedo M, Rosa P, Soares CT, et al. Analysis of immune response markers in Jorge lobo's disease lesions suggests the occurrence of mixed T helper responses with the dominance of regulatory T cell activity. *PLoS One*. 2015; DOI:10.1371/journal.pone.0145814.
- 2 Durden W, St. Leger J, Stolen M, et al. Lacaziosis in bottlenose dolphins (*Tursiops truncatus*) in the Indian River Lagoon, Florida, USA. *J Wildl Dis*. 2009; 45(3): 849-856.
- 3 Hart LB, Wells RS, Adams JD, et al. Modeling lacaziosis lesion progression in common bottlenose dolphins *Tursiops truncatus* using long-term photographic records. *Dis Aquat Org*. 2010; 90: 105-112.
- 4 Minakawa T, Ueda K, Tanaka M, et al. Detection of multiple budding yeast cells and a partial sequence of 43-kDa glycoprotein coding gene of *Paracoccidioides brasiliensis* from a case of Lacaziosis in a female Pacific White-sided dolphin (*Lagenorhynchus obliquidens*). *Mycopathologia*. 2016; 181(7-8): 523-529.
- 5 Murdoch ME, Reif JS, Mazzoil M, et al. Lobomycosis in bottlenose dolphins (*Tursiops truncatus*) from the Indian River Lagoon, Florida: Estimation of prevalence, temporal trends, and spatial distribution. *EcoHealth*. 2008; 5: 289-297.
- 6 Paniz-Mondolfi A, Talhari C, Hoffmann LS, et al. Lobomycosis: an emerging disease in humans and delphinidae. *Mycoses*. 2012; 55:298-309.
- 7 Reif JS, Mazzoil MS, McCulloch SD, et al. Lobomycosis in Atlantic bottlenose dolphins from the Indian River Lagoon, Florida. *Am Vet Med Assoc*. 2006; 228: 104-108.



Multifocal and coalescing raised, firm, white, 5-mm to 6-cm nodular lesions were identified on the rostrum, mandible, pectoral fins and dorsal fin, dorsum, peduncle and fluke of the affected dolphin.



The nodules formed large proliferative plaques up to 60 cm diameter, with a prominent central region of hypopigmentation





fungus, *L. loboi*, causes lobomycosis in humans, a nearly identical granulomatous skin condition, endemic in Central and South America. Humans and dolphins are the only known hosts for these unusual fungi. Originally described in Atlantic bottlenose dolphins near the Florida Gulf of Mexico coast in 1970, PC is now endemic in dolphins in the Gulf of Mexico and Florida Atlantic coast, with other recently identified infections in Brazil, Japan and the western Pacific.<sup>4,6,10</sup>

Transmission in dolphins and humans is thought to occur via inoculation of skin or through abrasions in contact with water. Lesions in dolphins are most prevalent on the leading edge of the fins, dorsum and the fluke, as well as in traumatic lesions. They consist of severe granulomatous and proliferative dermatitis, with granulation tissue and edema causing prominent hypo-pigmented and partially ulcerated nodules that eventually coalesce to form thick “keloidal” skin masses. Histologically, myriad yeasts are found both extracellularly and intracellularly within macrophages, measuring 6  $\mu\text{m}$  to 14  $\mu\text{m}$  in diameter, with a characteristic double refractile wall and arrangement in short chains interconnected by thin tube-like structures. Fungi are readily visible with H&E stains, but best visualized with Gomori methenamine silver or periodic acid-Schiff stains. Definitive diagnosis can be attained by PCR or IHC,<sup>10</sup> though culture of this organism has so far been impossible using conventional or experimental media and cell culture systems.<sup>11</sup>

### A ZOOONOTIC RISK?

PC is most common in adult and aged dolphins<sup>7</sup> and is progressive in most cases, often taking several years to develop large, confluent lesions.<sup>3,5</sup> Dolphins with marked morbidity often have extensive skin lesions in addition to significant pneumonia or other major systemic disease, consistent with advanced debilitation and likely immune suppression. Lesions may be singular or multifocal, but are contained to the dermis and subcutis with no visceral involvement.

Risk factors in dolphins are undetermined, but PC is common (12% to 17% of the population) in the southern regions of Florida’s Indian River Lagoon,<sup>5,7</sup> as opposed to the northern Indian River Lagoon, where prevalence is closer to 1%.<sup>5</sup> Why the spatial pattern occurs is unknown, but differences in water temperature and salinity have been suggested. Other hypotheses have focused on contamination with mercury, which may have an immuno-suppressive effect, leading to opportunistic infections with PC.<sup>8</sup> A novel study showed that affected dolphins there have impaired cell mediated immunity, with significantly decreased numbers of CD4<sup>+</sup> T cells and CD19<sup>+</sup> and CD21<sup>+</sup> B cells, as well as decreased MHC class II expression,<sup>8</sup> which may suggest predisposing immune suppression or, conversely, impaired adaptive immunity secondary to infection by the fungi.

Risk factors in humans include occupational exposures to soil, vegetation and particularly water. It is interesting to note that people with lobomycosis have significant local immune modulation characterized by a strong, though ineffective, Th2 driven humoral immune response, with prominent expression of IL-10, TGF- $\beta$ , CTL4 and FOXP-3 positive T regulatory cells with significantly decreased numbers of CD4<sup>+</sup> T cells.<sup>1</sup> T regulatory cell activity may be an important component of persistent disease in both dolphins and humans.

Though PC and lobomycosis share many similarities in humans and dolphins, current evidence suggests zoonotic transmission is highly unlikely, although a documented case exists.<sup>9</sup> Evidence against zoonosis includes morphologic differences in the organisms, recent specific molecular characterization of the dolphin organism as a novel *P. brasiliense*, failure to identify the human disease among 2.5 million people living close to the endemic Indian River Lagoon, differences in geographic distribution of the diseases and anecdotal evidence of lack of infection following accidental inoculations in people working with dolphin lesions.<sup>9</sup> ▲

8 Reif JS, Peden-Adams MM, Romano TA, et al. Immune dysfunction in Atlantic bottlenose dolphins (*Tursiops truncatus*) with lobomycosis. *Med Mycol*. 2009; 47: 125-135.

9 Reif JS, Schaefer AM, Bossart GD. Lobomycosis: Risk of zoonotic transmission from dolphins to humans. *Vector Borne Zoonotic Dis*. 2013; 13 (10): 689-693.

10 Sacristán C, Albergaria Réssio R, Catilho P, et al. Lacaziosis-like disease in *Tursiops truncatus* from Brazil: a histopathological and immunohistochemical approach. *Dis Aquat Org*. 2016; 117: 229-235.

11 Schaefer AM, Reif JS, Guzmán EA, Bossart GD, et al. Toward the identification, characterization and experimental culture of *Lacazia loboi* from Atlantic bottlenose dolphin (*Tursiops truncatus*). *Med Mycol*. 2016; 54:659-665.

12 Ueda K, Sano A, Yamate J. Case report: Two cases of Lacaziosis in bottlenose dolphins (*Tursiops truncatus*) in Japan. *Case Reports Veterinary Medicine*. 2013; Article ID: 318548:1-9.

13 Vilela R, Bossart GD, St. Leger JA, et al. Cutaneous granulomas in dolphins caused by novel uncultivated *Paracoccidioides brasiliensis*. *Emerg Infect Diseases*. 2016; 22(12): 2097-2103.

## CSU VDL in the Field: Case Studies

# Etiology Discovered for Large Death Loss on Colorado Ranch

— Charlie Davis, DVM, CSU VDL Coordinator

To fill a need for additional hay to supplement his cattle beyond the native grass hay routinely fed, a rancher on a 500-head ranch in northwest Colorado purchased a quantity of known poor-quality first-cutting 4-x-4 bales of alfalfa hay in early winter 2013 from a known source in Wyoming. The hay was primarily weeds, including annual kochia, sunflower, pigweed, lambs quarter, cockle bur, Russian thistle, salvia, flax, *Halogeton*, old corn stalks and various grasses. It was tested for nitrates prior to purchase and found to be acceptable for cattle feeding.

The cattle were worked in mid-December, as is routinely done on most ranches in western Colorado. The working included pregnancy testing, pre-calving multi-valent bacterial and viral vaccinations and injection with a chelated zinc, manganese, selenium and copper supplement. Open and cull cows received no vaccinations or injections. The cattle were divided into five different groups for management purposes based on age, sex and pregnancy status. Not uncommon at the 8,200-foot altitude at this location and time of year, the temperatures were -10° to -15° Fahrenheit for several days on end.

## WIDESPREAD, SUDDEN DEATHLOSS

On the morning of Dec. 18, 2013, one group of cull cows and yearling replacement heifers received two bales of the Wyoming-sourced hay only. Two groups of pregnant cows received a combination of native grass hay that had been fed for about one month previous, along with two bales of the Wyoming hay. Two of the five groups received no Wyoming hay. The common ranch practice is to feed cattle once daily this time of year.

The next morning, prior to feeding, a significant number of animals in the three groups fed the Wyoming

hay were noted to be ill, showing various stages of incoordination and anxiousness. A number were dead.

After summoning veterinary assistance, the owners, because they lived a significant distance from veterinary service, opened several carcasses. The experienced and knowledgeable owner reported the livers of those cattle opened were consistently “mushy,” with no other notable lesions. Later that day, the attending veterinarian collected numerous necropsy, feed and water samples. Symptomatic treatment of clinically ill cattle was unsuccessful, and within 72 hours, 175 died.

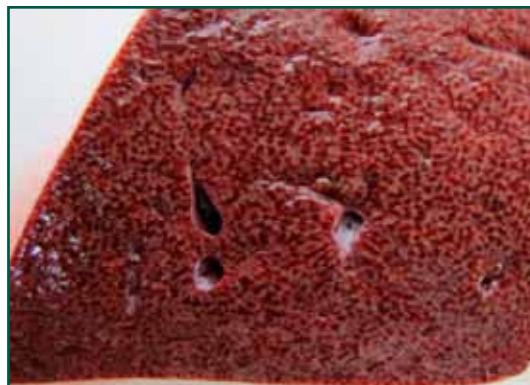
## REACHING OUT: SEARCH FOR ETIOLOGY BEGINS

Initial testing of body tissues, blood samples, aqueous humor samples, rumen contents, and feed and water samples at the CSU VDL Grand Junction lab, the main laboratory in Fort Collins and additional labs revealed only one consistent finding: histologically severe acute hepatic necrosis. But none revealed an etiology of the hepatic necrosis.

The Colorado State University Field Investigation Unit was summoned, which provided significant additional knowledge resources, and in February 2014, the Veterinary Laboratory Investigation and Response Network (VET-LIRN), an FDA-based group, was also engaged. That networking group was a great resource to introduce for not only additional laboratories but also additional testing in the attempt to decipher the cause. Tests for known hepatic toxins included aflatoxins, mycotoxins, heavy metals, microcystins, alkaloid screens and acarboxyatractiloidase. Still, all were unfruitful.

Because the only change from routine was the feeding of the Wyoming hay, the hay was suspect from the

This wide-ranging investigation began with (from left, below and opposite) feeding hay that resulted in more than 175 deaths within 72 hours. Gross livers were reported as “mushy” with no other notable lesions. Investigators managed to collect all remaining suspect hay from the ranch as well as the original source farm, which was analyzed to eventually discover the causative toxic plant.








start. Kip Panter, research leader at the USDA Poisonous Plant Identification Laboratory in Logan, Utah, was brought in. Based on a history of supposed Kochia involvement in other bovine deaths in which nitrate was ruled out, it was “vaguely accepted” that Kochia or some weed combination with Kochia was to blame in this case. However, based on their experience several individuals didn’t accept the proposition—particularly Panter. Although Kochia was the predominate plant in this hay, it is known to be a decent feed source in terms of protein content, so long as the nitrate levels are acceptable. Such was the case with this hay.

### TOXIN HIDDEN IN PLAIN SIGHT

Panter was able to obtain 10 cows from the Colorado ranch, some of which had survived clinical involvement and some that appeared clinically normal throughout. He was also able to obtain all the remaining Wyoming hay, including from both the Colorado ranch and the Wyoming source.

He conducted various feed trials on ranch cows, unrelated steers and goats. Liver involvement was consistent, with some animals sacrificed due to illness from the feed while others demonstrated liver damage on biopsy as well as clinical pathology tests. One interesting notation was that ranch cows that had gotten sick from eating the hay initially were averse to it when Panter presented it to them during the trials.

Panter went through each bale in an organized and in depth manner. In doing so, he discovered a significant amount of the plant *Salvia reflexa*, or wild mint. It had not been noted in a seemingly significant amount previously.



His careful analysis revealed that the wild mint (*Salvia reflexa*) was inconsistent throughout the hay, but portions of some bales contained enough to make the amount significant overall. On-site investigation at the Wyoming field confirmed growth patterns in certain patches in the field along with the baling pattern at harvest likely caused the localized concentrations within bales.

Once the *Salvia reflexa* was noted, carefully planned goat and calf feed trials of the plant species alone gave indication of liver involvement. Working with the chemist at his lab in Logan, Panter extracted toxins from the plants and developed a bioassay-guided fractionation using the mouse model to identify the toxins chemically. Administering the toxin resulted in severe acute hepatic necrosis identical to the experience in the original ranch cattle, providing a certain sense that *Salvia reflexa* was the causative agent. Histologic studies revealed similar pathologic lesions in cattle, goats and mice, with only technical species differences noted. The toxins extracted in pure form were identified as salviarin, rhyacophilin and derivatives of each. The salviarin proved the most toxic.

Growth of the *Salvia reflexa* plant in a greenhouse setting from seeds obtained from the hay provided the noted toxin and resulted in liver involvement when administered in pure form to the mouse model. The aversion to the hay by cows that had been sickened by it previously was not a surprising finding. Most often, plant seeds tend to be the most toxic part of a plant, but in the case of the *Salvia reflexa*, the seed pods were most toxic with leaves and flowers being next.

It’s important to note that *Salvia reflexa* contains both annual and perennial subspecies. The annual is the one proven toxic in this workup. Numerous species of *Salvia* exist, with many used as decorative yard and garden plants. Some reports of human herbal use of certain *Salvia* species should be noted and of concern!

Panter and his co-workers are to be commended for their diligence and persistence in reaching a conclusion to this extensive cattle deathloss case. Their discovery is of significant potential importance not only to the livestock industry but also to ranchers and farmers who grow hay for their own use or for sale as their sole source of income. ▲

Hidden in plain sight within the hay bales by localized inconsistency of growth patches and harvest patterns, *Salvia reflexa* (left) proved to be the causative agent. Toxin extracted from greenhouse samples grown from the suspect hay seed caused gross liver pathology in mice dosed with the toxin (at right, above) compared to normal.

(*Salvia* photo courtesy KE Panter, USDA-Agricultural Research Service, Poisonous Plant Research Laboratory, Logan, Utah.)

### DIAGNOSTIC APPROACH LESSONS LEARNED

- In such a suspected toxicity case, samples of tissues, blood and serum, as well as intestinal contents and feed sources, should be reasonable but plentiful. Too many samples are far better than not enough.
- Thoroughness and attention to detail are imperative at all stages—as should be for any diagnostic challenge.
- Listen closely to owners for suggestions or hints to unknown factors.
- Be willing to network and seek resources, particularly in more difficult cases.

CSU VDL In Press

# A Roundup of VDL Faculty Research

## CANINE COLLISION TUMOR CHARACTERISTICS

Scott JE, Liptak JM, Powers BE. Malignant collision tumors in two dogs. *J Am Vet Med Assoc.* 2017 Oct 15;251(8):941-945. doi: 10.2460/javma.251.8.941.

Working with colleagues in Ontario, VDL Director Barb Powers searched the lab database from 2008 through 2014 for canine patients with histology reports that indicated collision tumors. A collision tumor is a mixed tumor, a neoplasm that macroscopically represents one tumor but histologically or immunohistologically contains two or more components. In a collision tumor, two adjacent foci of neoplasia develop independently and separately. True collision tumors in people and other animals are rare, with little known about treatment and outcomes—the English-language literature contains just a single case report of a nontesticular collision tumor in a dog. The origin and importance of collision tumors are unknown, and several theories as to their etiopathogenesis exist.

Powers' search yielded 39 cases which were eventually classified as collision tumors. Among those, the most common combination of tumors was a mast cell tumor and a soft tissue sarcoma (n = 10). The second most frequent collision tumor was com-

posed of a hemangiosarcoma and a carcinoma, with 6 cases recorded, of which 4 were dermal in origin. Four dogs with hepatic collision tumors were identified; each collision tumor involved a primary hepatocellular carcinoma and adjacent hemangiosarcoma. The outcomes following complete surgical excision of the collision tumors for the two dogs of the case report were similar to outcomes expected following complete surgical excision of any of the individual tumor types in dogs. Wide surgical excision of a collision tumor should be the initial treatment; however, surgical planning may be difficult owing to the inability to identify collision tumors on the basis of gross appearance or cytologic findings alone. Adjunctive treatments, such as chemotherapy or radiation therapy, should be considered depending on the histopathology completeness of excision.

## TRACKING POX IN ENDANGERED ALBATROSS

Tompkins EM, Anderson DJ, Pabilonia KL, Huyvaert KP. Avian Pox Discovered in the Critically Endangered Waved Albatross (*Phoebastria irrorata*) from the Galápagos Islands, Ecuador. *J Wildl Dis.* 2017 Oct;53(4):891-895. doi: 10.7589/2016-12-264.

VDL Avian Section Head Kristy Pabilonia collaborated with CSU Fish, Wildlife and Conservation Biology and Tufts researchers to investigate 14 cases of avian pox in the critically endangered species of waved albatross,



Tumor 1	Tumor 2	Complete excision?	Location
<b>Collision tumors</b>			
Adenocarcinoma	Pheochromocytoma	Yes	Adrenal gland
	Osteosarcoma	Yes	Kidney
Anal sac apocrine gland adenocarcinoma	Infiltrative lipoma	Yes	Perianal region
Carcinoma	Chondrosarcoma	Marginal	Ear
Fibrosarcoma, grade III*	Mast cell tumor, grade II*	Yes*	Left flank*
	Melanoma	Yes	Cutaneous
	Melanoma	No	Hip region
	Adenocarcinoma, grade III	Unknown	Lungs
Hemangiosarcoma	Fibrosarcoma, grade II	Yes	Tarsal region
Hemangiosarcoma, grade II	Melanoma	Yes	Prepuce
Hepatocellular carcinoma	Hemangiosarcoma	Unknown	Liver
	Hemangiosarcoma	Unknown	Liver
	Hemangiosarcoma	No	Liver
	Hemangiosarcoma, grade III	No	Liver
Mast cell tumor	Malignant lymphoma	Yes	Axilla
Mast cell tumor, grade II	Plasma cell tumor	No	Cutaneous
	Myxosarcoma, grade I	No	Body wall
	Malignant melanoma	Marginal	Cutaneous
	Soft tissue sarcoma, grade I	Marginal	Cutaneous
Mast cell tumor, grade III	Melanoma	Unknown	Eyelid
	Hemangiosarcoma, grade I	Yes	Thigh region
Melanoma	Mast cell tumor, grade II	Yes	Cutaneous

Tumor 1	Tumor 2	Complete excision?	Location
Metastatic osteosarcoma	Adenocarcinoma	Necropsy	Lungs
Soft tissue sarcoma	Hemangiosarcoma	Yes	Spleen
Soft tissue sarcoma, grade I	Mast cell tumor grade II	Yes	Ischium
	Mast cell tumor, grade II	Marginal	Thorax
	Mast cell tumor, grade II	Yes	Cutaneous
	Extraskeletal osteosarcoma	Yes	Cutaneous
Soft tissue sarcoma, grade I (peripheral nerve origin)	Mast cell tumor, grade II	No	Cutaneous
Soft tissue sarcoma, grade II	Mast cell tumor, grade II	Marginal	Shoulder region
	Mast cell tumor, grade II	No	Cutaneous
Squamous cell carcinoma	Soft tissue sarcoma (smooth muscle)	Unknown	Nasal region
	Lymphoma	No	Mammary gland
	Hemangiosarcoma, grade II	No	Inguinal region
	Malignant melanoma	No	Tail
	Hemangiosarcoma	Yes	Inguinal
Thyroid carcinoma	Undifferentiated sarcoma	Marginal	Thyroid gland
<b>Collision and colonized tumors</b>			
Apocrine sweat gland adenocarcinoma	Chondrosarcoma	Yes	Cutaneous location
Perianal gland carcinoma*	Hemangiosarcoma, grade I*	Yes*	Perianal region*
<b>Combination tumors</b>			
Chondrosarcoma, grade II	Liposarcoma, grade I	Yes	Thoracic wall
<b>Composite tumors</b>			
Adenocarcinoma	Squamous cell carcinoma and osteosarcoma	Yes	Cutaneous location





Photo: Flickr/Dan. Some rights reserved. Used under CC BY-SA 2.0.

*Phoebastria irrorata*, and its possible transmission mechanisms. The birds, which breed almost exclusively on Española Island in the Galápagos Archipelago, face risk of rapidly shrinking population and threats of mortality in artisanal fisheries and introduction of novel pathogens. Recent increases in avian pox may have contributed to population declines and range contractions.

The researchers identified eight infected nestlings on the first of three surveys and six more on the second and third surveys, a prevalence of 8%, 7% and 4%, respectively. None of the 60 adult albatrosses or 231 landbirds surveyed in the focal area had detectable lesions. Although histopathologic examination of four sections of the samples from four different nestlings revealed lesions consistent with pox infection, attempted real-time avipoxvirus PCR confirmation was unsuccessful.

The colony has been monitored annually since 1999 without sign of avipoxvirus, so this may be the first appearance in the population. The source is unknown, but spillover from infected landbirds through fomites, or via mechanical transmission by biting arthropods are possible sources. The sudden appearance of this disease in a critically endangered species is concerning, and increased effort into vector identification is warranted.

### SOFT TISSUE SARCOMA IN A SHARK

Camus AC, Ibrahim MM, Alhizab FA, Aboellail TA, Ibrahim AM.

Poorly differentiated soft tissue sarcoma in an Arabian carpet shark *Chiloscyllium arabicum* (Gubanov): A case report. *J Fish Dis.* 2017 Jul 14. doi: 10.1111/jfd.12683.

VDL Pathologist Tawfik Aboellail collaborated on this international case report describing the first tumor involving smooth or skeletal muscle in a Chondrichthyan species. Chondrichthyan fish—sharks, skates, rays and chimaeras—have received attention for a


purported absence or low incidence of cancer, and some extraordinary claims have been made regarding shark cartilage as antineoplastic therapy.

In this report, a wild-caught Arabian carpet shark, *Chiloscyllium arabicum* (Gubanov), a small bamboo shark of the family *Hemiscylliidae*, exhibited a superficially ulcerated, 3 cm by 2.5 cm mass raised 1 cm above the skin near the base of the second dorsal fin.

The moderately cellular neoplasm was composed of loosely and haphazardly arranged cells within a scant and poorly vascularized stroma. Anisocytosis and anisokaryosis were marked. Large, irregularly round or ovoid to polygonal cells dominated the tumor, with abundant finely granular to fibrillar eosinophilic cytoplasm. Nuclei were large and primarily round to oval, with occasional elongate and irregular forms, containing stippled to vesicular chromatin and one or infrequently two, large, intensely basophilic nucleoli. Nuclei were rarely peripheralized and sometimes compressed by discrete, pale eosinophilic to hyaline cytoplasmic inclusions. Fusiform, spindlyoid and straplike cells were scattered throughout. Bizarre multinucleated cells and cell-to-cell moulding were occasionally present. Other, less differentiated, small round cells with a thin rim of granular eosinophilic cytoplasm surrounding a small hyperchromatic nucleus were widely distributed in small numbers, but infrequently formed larger collections. Additional features included tumor cell phagocytosis.

Although multiple approaches were attempted, interpretation of this neoplasm presented a diagnostic challenge, and a definitive diagnosis could not be reached. The mass and location and cell structure suggested rhabdomyosarcoma, but other poorly differentiated, pleomorphic soft tissue sarcomas could not be ruled out.

Despite the locally invasive nature of the neoplasm, no mitotic activity was observed in 10 high-power field, and researchers found no macroscopic evidence of metastasis. For unknown reasons, many fish tumors exhibit fewer signs of malignancy, behave less aggressively and metastasize much less frequently than mammalian counterparts. ▲



Paulo Oliveira/  
Alamy Stock Photo



CSU VDL In Press

## VDL Award-Winning Research

At the CSU Veterinary Diagnostic Laboratories, one of our missions is to strive to contribute to research to develop new approaches to disease identification, investigation and prevention. Some of the best of that research was presented at the following conferences.

### COMPARATIVE CANINE, HUMAN LYMPHOMA

**Harris L, Hughes K, Ehrhart EJ, Yoshimoto J, Burnett R, Avery A.** Gene expression profiling identifies canine CD4+ T-cell lymphoma as a naturally occurring model of an aggressive subset of human peripheral T-cell lymphoma-not otherwise specified. Paper presented at: 2017 American College of Veterinary Pathologists Annual Meeting; 2017 Nov 4-8; Vancouver, B.C.

Peripheral T-cell lymphoma-not otherwise specified (PTCL-NOS) is a heterogeneous group of neoplasms with grave clinical outcomes in both canines and humans. Because PTCL-NOS is relatively uncommon in humans, an appropriate model is needed to facilitate further investigation. We investigated whether canine PTCL could serve as that human model.

We RNA-sequenced and analyzed lymph-node aspirates from six dogs diagnosed with CD4+ PTCL and sorted CD4+ T-cells from control dogs and then compared the results to similar studies on human PTCL-NOS.

Results showed canine CD4+ PTCL is molecularly similar to aggressive human PTCL-NOS and serves as a useful model. Both human and canine PTCL-NOS upregulate pathways involved in proliferation, cell adhesion, extracellular matrix modification and signal transduction. Canine cases overexpress GATA3 and CCR4, two markers that in humans characterize a distinct subset associated with worse clinical outcomes.

GATA3 expression is corroborated by immunohistochemistry and may serve as a histologic marker. Overexpression of PGDFR is also conserved across both human and canine cases and have been suggested as a potential therapeutic target.



CSU VDL Anatomic Pathology Resident Lauren Harris won third place in the Young Investigator award in the Natural Disease Category at the 2017 annual meeting of the American College of Veterinary Pathologists.

### DIFFERENTIAL IMMUNOHISTOCHEMISTRY PANELS?

**Andrie KM, Pannone S, Santangelo KS.** Development of an immunohistochemistry panel for differentiating mesothelial hyperplasia from malignant mesothelioma in dogs. Paper presented at: 2017 American College of Veterinary Pathologists Annual Meeting; 2017 Nov 4-8; Vancouver, B.C.

Immunohistochemistry panels have proven useful in humans for differentiating the diagnostically challenging malignant mesothelioma, mesothelial hyperplasia and pulmonary adenocarcinoma. Our team's goal was to validate whether similar tests using immunobiomarkers, including epithelial membrane antigen, p53, desmin, calretinin, glucose transporter 1, and insulin-like growth factor II messenger RNA-binding protein 3, can accurately diagnose cases in dogs that are ambiguous based on histopathology alone.

We evaluated 60 archived canine tissues for expression of calretinin, desmin and EMA/Muc-1 with the aim of developing a novel diagnostic immunohistochemistry panel. Our work thus far has revealed that the pattern of desmin and calretinin immunolabeling may not mimic that described in humans. Desmin may be nonspecific for both hyperplastic and neoplastic mesothelial tissue, and all cases in our cohort were immunonegative for calretinin. We are continuing our work to validate EMA/Muc-1 and GLUT-1 expression. Our findings emphasize the perplexing immunohistochemical profile of canine disorders of mesothelial origin.

### FETAL LOCOWEED SUSCEPTIBILITY

**Betley M, Stegelmeier BL, Niles G, Frank C.** Multiple cases of bovine abortion associated with locoweed ingestion in non-clinical dams from Southeastern Colorado. Poster presented at: 2017 American College of Veterinary Pathologists Annual Meeting; 2017 Nov 4-8; Vancouver, B.C.

Chronic ingestion of certain species from the genera *Oxytropis*, *Astragalus*, *Ipomeoa* and *Swainsonia*, colloquially known as locoweeds, is well known to induce locoism. Poisoning in adult cattle is characterized by sensory deficits, ataxia, behavior changes, loss of condition and failure to grow. The toxic principle swainsonine is rapidly absorbed and distributed through the bloodstream to multiple organs, where it inhibits lysosomal alpha-mannosidase and Golgi mannosidase II leading to lysosomal dysfunction and disrupt-



CSU VDL Anatomic Pathology Resident Kendra Andrie won a travel grant for the 2017 annual meeting of the American College of Veterinary Pathologists.



tion of glycoprotein processing. Excessive mannose accumulation causes cytoplasmic vacuolation and cellular dysfunction. Chronic consumption of locoweeds is most commonly associated with disease in adult animals and abortion in affected, neurologic dams. However, we report multiple cases of bovine abortion associated with chronic locoweed ingestion in non-clinical dams from a Colorado herd. Neurons from the cerebral cortex, brainstem, cerebellum and renal tubular epithelial cells in the aborted animals display characteristic cytoplasmic vacuolation observed in adult cases. Our findings indicate fetuses may be more sensitive to maternal locoweed ingestion than previously suspected.



CSU VDL Anatomic Pathology Resident Mike Betley won a travel grant for the 2017 annual meeting of the American College of Veterinary Pathologists.

### RESPIRATORY NIDOVIRUS IN BALL PYTHONS

Hoon-Hanks LL, Layton ML, Ossiboff RJ, Dubovi EJ, Stenglein MD. Respiratory disease in pythons experimentally infected with python nidovirus and other updates on this emerging veterinary disease. Paper presented at: 2017 American College of Veterinary Pathologists Annual Meeting; 2017 Nov 4-8; Vancouver, B.C.

We conducted an experimental infection in ball pythons (*Python regius*) to test the hypothesis that a novel ball python nidovirus (BPNV) infection would yield clinical signs and histologic lesions consistent with respiratory disease and help explain an emerging severe respiratory illness of pythons observed by veterinarians since the 1990s.

We injected three juvenile ball pythons with BPNV-infected medium and two with uninfected medium. Antemortem swabs were performed weekly and tested for BPNV RNA by PCR. Euthanasia and postmortem examination were performed on infected snakes at 5 weeks, 10 weeks, and 12 weeks post-inoculation, based on clinical signs.

The most significant lesions in the infected snakes included chronic-active catarrhal rhinitis, stomatitis, tracheitis, and esoph-



CSU VDL Anatomic Pathology Resident Laura Hoon-Hanks won a travel grant for the 2017 annual meeting of the American College of Veterinary Pathologists.

agitis with variable epithelial proliferation and an interstitial and proliferative pneumonia. Infectious virus was recovered from swabs and tissues from infected snakes. Control snakes remained negative. Our findings establish a causal relationship. BPNV is part of an expanding group of related viruses associated with respiratory disease in reptiles and mammals.

### THYMOMA-ASSOCIATED GOAT DERMATITIS


Byas AD, Kunkel A, Applegate T, Frank CB. Thymoma-associated exfoliative dermatitis in a goat. Poster presented at: 2017 American College of Veterinary Pathologists Annual Meeting; 2017 Nov 4-8; Vancouver, B.C.

We report the first incidence of thymoma-associated exfoliative dermatitis in a goat. The 9-year-old rock alpine doe presented with progressive scaling and ulceration over the withers, coronary bands and dew claws. Radiographs revealed a large cranial mediastinal mass. Necropsy revealed marked exfoliative to ulcerative lesions of the dorsum, ventrum, pinna, neck, teats, coronary bands and dewclaws and a large multifocally cystic, soft, white, encapsulated mass. Histopathology of the cranial mediastinal mass showed a cytokeratin-positive epithelial neoplasm with marked infiltrates of non-neoplastic CD<sub>3</sub>-positive lymphocytes, consistent with a lymphoepithelial thymoma. Histopathology of the skin lesions demonstrated a hyperkeratotic interface dermatitis and folliculitis with apoptosis of the stratum corneum, spinosum and basale as well as the follicular epithelium. Recognition of this entity in goats is diagnostically important as thymomas are prevalent in goats but frequently lack associated clinical signs. This syndrome should be considered as a clinical differential in caprine dermatologic lesions.

### ATYPICAL PERIPHERAL ODONTOGENIC FIBROMAS

Curtis B, Schaffer P, Frank CB. Clinical features and pathology of hypercellular canine peripheral odontogenic fibromas. Poster presented at: 2017 American College of Veterinary Pathologists Annual Meeting; 2017 Nov 4-8; Vancouver, B.C.

We retrospectively surveyed referrers of a subset of peripheral odontogenic fibromas with increased cellularity, mitotic figures and increased nuclear and cellular pleomorphism. Of the 12 dogs with follow-up data, nine were still alive, and the three deaths were due to unrelated disease. Two had recurrence of the oral mass, but following further excision remained disease free. Metastasis was not reported in any case. No therapy was elected beyond local resection. Atypical presentations of POFs do not appear to be associated with metastasis or a poorer prognosis compared to histologically typical POFs. ▲



## Get to Know the Laboratory

# New Members Join the Lab Team

**Thomas Peppard** is a new bacteriology technician in the Bacteriology and Serology Department. He grew up across the United States but calls Colorado home. He graduated from University of Colorado Colorado Springs with a bachelor's degree in biology. Enjoys running with his German shepherd, fishing and painting fine-scale models.



**Sara Watson**, VDL's newest laboratory technician in the Molecular Diagnostic Department, finished her master's degree in biomedical science at CSU and started working as the training coordinator at CSU's Laboratory Animal Resources. She was a research associate in a CSU neuroendocrinology lab involved with investigating sex differences in brain stress responses. She has committed her life to animal welfare in a research setting but is excited to pursue professional development in diagnostics. Outside work she enjoys snowboarding, cycling, hula hooping and spending time with her husband and 14-month old son, Orion.



**Jeff Nelson** is the new Western Slope VDL technician. A South Dakota native and Colorado transplant, he graduated from University of South Dakota with a medical biology degree and gained some graduate experience from USD in basic biomedical sciences the following year. His previous experience in lab settings led him to seek out this job. He enjoys running, reading, hiking, watching movies and spending time with family and friends.



**Heather Reider** is the new avian health program coordinator. She recently moved back to Colorado from Alaska but also has roots in Minnesota. A graduate of CSU with a masters of business administration, Reider has spent her professional career managing wildlife-research projects from



the Antarctic to the Arctic, with a strong focus on avian research. She enjoys traveling, hiking, backpacking, skiing, road biking and spending time with her 6-year-old son, Maxton.

**Garrett Tacha** is the new Necropsy Lab technician. He was born and raised in Lenexa, Kan. He attended Kansas State University and obtained a degree in agriculture, studying animal science and biotechnology. He worked as an animal technician at Merck Animal Health for two years before relocating to Fort Collins. He is also working on applying to a graduate program within the MIP department.



**Amy Rich**, who always had a strong affinity for medical sciences and a passion for animals, finally realized her dream of working in both when she started working with a northern Colorado emergency veterinarian. She graduated from Front Range Community College with an associate of applied sciences degree in veterinary technology. She also has done general veterinary practice work, both in brick-and-mortar and mobile practices. She came to CSU in 2016 as a clinical educator teaching Foundations and then moved to lab support in the Tissue Trimming Section of the Diagnostic Medicine Center in March 2017. In addition to two children Amy and her spouse have one spunky chihuahua terrier mix she rescued at the ER.



**Karisa Sommermeyer** is the new Parasitology Section laboratory technician. A Fort Collins native, she graduated from CSU with a bachelor's degree in biological sciences with a minor in biomedical sciences, and a bachelor's degree in science and microbiology. Her hobbies include playing the piano, singing, reading and watching movies. She is also an avid dog lover and has a 7-year-old Newfoundland.



Five of CSU's anatomic pathology residents passed the board certification examination, recognizing entry-level competency in veterinary clinical pathology and veterinary anatomic pathology. Some have suggested the ACVP certification is the most rigorous and best-designed certification process within all veterinary medical specialties. Congratulations to:

- Laura Hoon-Hanks
- Allison Vilander
- Craig Miller
- Jenn Malmberg
- Claire Hoover



**Mac Harris**, new pathology resident, grew up in western Connecticut on his family's rescue and therapeutic riding facility. Medicine seemed like a natural choice as he entered undergraduate study at University of Connecticut. While there, he was introduced to veterinary pathology, which led to work at the Connecticut state diagnostic lab as a necropsy technician, along with pursuing a double major in animal science and veterinary pathobiology. During undergraduate studies, he gained an appreciation for infectious diseases, specifically pathogenesis and host interaction, by working as a research assistant for a project attempting to develop a necrotic enteritis toxoid in chickens. Harris' interest in pathology and research continued to develop throughout his veterinary curriculum at North Carolina State University. His infectious disease interest solidified while working on a research project involving *Enterococcus cecorum* causing enterococcal spondylitis in chickens.



**Devin von Stade**, new pathology resident, didn't know he wanted to be a veterinarian until he had almost finished college at Pitzer College in California, nor that he wanted to go into pathology until near the end of veterinary school at University of California-Davis. Always one who had a need to understand how things worked, his early rediscovered interest in research led to co-designing a mathematical model for behavior based on skeletal proportions using birds as an example, a learning experience that opened him up to the possibilities of interdisciplinary, collaborative research as a career. The resulting need for a specific skill set led him to veterinary school. After projects in disease surveillance and diagnostic technology development, he found that anatomic pathology was the area that really gripped him. Von Stade's research interests are primarily in method development of imaging tissue pathology and in the application of diagnostics to field-ready testing, both molecular and digital. ▲



## CSU VDL ON THE ROAD: UPCOMING CONFERENCES, SYMPOSIA AND APPEARANCES

VDL Director **Barb Powers**, VDL Avian Diagnostics and BSL3 Operations Section Head **Kristy Pabilonia**, Western Slope Lab Director **Raye Walck**, Virology Section Head **Christie Mayo**, Quality Assurance Manager **Dwayne Hamar**, Pathologist **Juan Muñoz**, Rocky Ford Lab Manager **Jane Carman Wharry** and Quality Assurance Assistant Manager **Kevin Daniels** represented the lab at this year's annual meeting of the **American Association of Veterinary Laboratory Diagnosticians**, Oct. 12 to 18 in San Diego.

In June 2017, **Walck**, along with Rocky Ford Lab Director **Gene Niles** and VDL Coordinator **Charlie Davis**, attended the **Colorado Cattlemens Association** meeting in Grand Junction. **Davis** also attended the **99th Colorado Wool Growers Convention**, in July 2017 in Montrose.

Pathologist **Chad Frank** attended the **American College of Veterinary Pathologists** meeting, Nov. 4 to 8 in Vancouver.

Lab Coordinator **Davis**, along with **Powers**, **Mayo** and Bacteriology Section Head **Josh Daniels**, was in attendance at the **Colorado Cattlemens Association** mid-winter conference in Denver in January 2018. He also attended the January **Colorado Wool Growers** winter meeting in Denver.

Look for him also at the **Colorado Cattlemens Association** annual meeting in June. **Davis** attended the **Colorado Cattlemens Association August** planning session in Pueblo, spoke at the **Colorado Veterinary Medical Association** meeting in Loveland, Sept. 21-24, and has conducted or attended several outreach meetings, including the **Beef Cattle Field Day and Pasture Tour** in August at ARDEC. He also has several planned tours of ranches and livestock facilities scheduled this year for VDL personnel. If you would like to host a tour, please contact him at the lab.

VDL Pathologist **Sushan Han** presented the case study of lobomycosis in the Atlantic bottlenose dolphin (see page 6 of this issue) at this year's 49th annual conference of the **American Association of Zoo Veterinarians**, Sept. 23 through 27 in Dallas.

Western Slope Lab Director **Raye Walck** attended the **Colorado Veterinary Medical Association** meeting in Loveland, Sept. 21 to 24. Look for her at the association's **CE West** meeting in Palisade, June 1 through 3. She will also be in attendance at the **Colorado Wool Growers** 91st annual convention, July 11 and 12 in Montrose.



Congratulations and thanks to Bacteriology Lab Technician **Denise Bolte** and her daughter, **Lauren**, who organized this season's VDL giving tree, which resulted in delivery of a sleigh full of donated bags, toys, cleansers, leashes, food and more gifts to the Animal House and Larimer Humane Society.

**REGULAR COLUMNS**

- **LAB UPDATES** p. 1  
Meet our new pathologists.
- **LAB QA** p. 4  
Pro tips for urine submission.
- **LAB UPDATES** p. 14  
New team additions.
- **ON THE ROAD** p. 15  
Where and when you can meet our faculty.

**LAB LINES**

- SAMPLE QA** . . . . . p. 2  
Packing and shipping histopathology samples for success.
- ZOO CORNER** . . . . . p. 4  
CSU VDL assists in case study of Paracoccidiomycosis ceti in an Atlantic Bottlenose Dolphin.
- CASE STUDY** . . . . . p. 8  
Tracking down the etiology of a case of large deathloss in a Colorado beef herd.



**INSIDE THIS ISSUE**

- MOLECULAR TOOLS** . . . . . p. 6  
New innovations to find the needle in the haystack of polymicrobial complexes.
- VDL'S LATEST RESEARCH** p. 10  
The latest studies from VDL faculty members.
- AWARD-WINNERS** . . . . . p. 12  
A round-up of research recognized at the recent ACVP conference.



**Update from the Director**

**TO CONTACT  
 BARB POWERS:**  
 Call (970) 297-1281  
 or email  
 DLAB@colostate.edu

Welcome to this issue of *LabLines*. Be sure to take a look at the front page of the issue, where we highlight the two new pathologists who have joined the laboratory. We are very excited to have their new perspective and energy that new faculty bring. They are already quite busy providing excellent service to all clients. You will also notice on pages 14 and 15 that we also have a number of new staff members in various sections. In addition, our new residents joined us in July.



**BARBARA POWERS,  
 DVM, PHD, DACVP  
 DIRECTOR**

In this issue of *LabLines*, you will find articles that range from how best to submit samples to research done by the faculty, staff and students of the laboratory. We also present case reports from a variety of species, from dogs to dolphins to sharks.

Also inside, you'll read a case in which the mysterious cause of a large death loss at a Colorado beef-cattle ranch was finally solved by the work of our Field Investigation Unit, working in collaboration with USDA. This case study is a reminder that the Field Investigation Unit is available to help with livestock issues and is a service provided to all of Colorado by our laboratory and the university. It is designed to actively bring all the universi-

ty's multidisciplinary veterinary resources to bear on production problems faced by Colorado livestock producers, identify underlying production or disease issues and solve them with research-based strategies.

Inside, you will also find an update on exciting new advances in molecular diagnostics using CRISPR technology which has won our faculty national recognition.

You may have noticed that we had a very successful implementation of our new Laboratory Information Management System, so your reports look different. We also implemented a new accounts-receivable program to make our bills more understandable. These were mentioned in the last issue of *LabLines*, but if you have any comments about the new reports or invoices, please give us a call so we can make any adjustments that are needed.

Recently in January we held our annual External Advisory Committee meeting, which provides valuable insight and feedback to our laboratory. Most importantly, they confirmed that our role is to provide quality and timely service to you, all of our clients. Please call us if you have any comments or questions.

*Barbara E. Powers*