



LAB LINES

Diagnostic news and trends from the Colorado State University Veterinary Diagnostic Laboratories
Volume 18, Number 2
Fall/Winter 2013

Lab Updates

VDL Pathologist Patricia Cole Named CVMA Outstanding Faculty

This year's Colorado Veterinary Medical Association outstanding faculty award honors a member of the CSU Veterinary Diagnostic Lab who instills a love for the profession into her students. Pathologist Patricia Cole, her students say, shows them this passion every day, rather than just telling them.

The award, given annually, recognizes a Colorado State University faculty member who has provided unselfish assistance to practitioners as a clinician, is a proficient and capable teacher, or has made significant contributions to continuing education.

"First of all," Cole says, "I am proud to be a veterinarian. People in our profession have many different roles and we all work together to further animal health and wellbeing. I feel privileged to play my part through my work at CSU. I have taught pathology to over 3,000 veterinary students, helping them prepare for their careers. And in my work as a pathologist, I can help animals by providing diagnostic services that help other veterinarians do their work."

Cole says she has as much fun teaching the students as they seem to have learning from her. She says that the one thing they seem to remember about her classes is the little art history session she likes to lead at the beginning of the hour, sharing art that features animals. She also likes to show off her own animals from time to time. She has quite a few at home, including three horses.



CSU VDL Pathologist Patricia Cole (left) with CVMA Immediate Past President Randa MacMillan after accepting her award for outstanding faculty member at this year's CVMA meeting.

Says one student, "We tend to set expectations for our instructors. However,...we don't always acknowledge those that go above and beyond. Dr. Cole is a prime example of a gifted instructor we have grown to appreciate."

We congratulate Pat Cole for receiving the 2013 Outstanding Faculty Award. ▲

PAST HONOREES

2012 Khursheed Mama
2011 Jane R. Shaw
2010 Kathy Lunn
2009 Susan Lana
2008 Rodney A. Rosychuk
2007 Kristy Pabilonia
2006 Hana Van Campen
2005 Richard D. Park
2004 Dean Hendrickson
2003 Josie Traub-Dargatz
2002 Barb Powers
2001 Anthony Knight
2000 Michael Lappin
1999 David Twedt
1998 Gayle Trotter
1997 Ted Stashak
1996 Gregory Ogilvie
1995 Stephen Withrow
1994 Jack Lebel
1993 Robert Shideler
1992 Donald Piermattei

MILK TESTING OPTIONS

- Somatic Cell Counts ..50¢
 - Charm antibiotic residue testing.....\$10 to \$15
 - Raw Milk panels
Association member
panel.....\$25
- Many more milk testing options are available. Visit our web site or give us a call.

EXPANDED MILK-TESTING OPTIONS NOW AVAILABLE

As part of our new focus on dairy mastitis and milk testing, VDL now offers these new testing options:

- Somatic Cell Counts. Somatic Cell Counts (SCCs) are a valuable test to help determine the quality of the milk and to indicate whether mastitis may be occurring.
- Charm antibiotic residue testing. We are capable of testing milk for many different antibiotics, including beta-

lactams, sulfonamides, tetracycline and others. The Charm test is ideal for dairies concerned that they may be at risk of antibiotic residues.

- Raw milk panels. VDL now offers two different raw milk panels: One specifically for members of the Raw Milk Association; the other, a full work-up including every pathogenic bacterium we test raw milk for. We have currently added *Salmonella*, *E.*

coli 0157-H7, *Campylobacter* and *Listeria* to raw-milk tests. All tests employ Standard Methods for the Examination of Dairy Products or Food & Drug Administration guidelines. These standards are superior to most regular microbiological methods and ensure the best possible result from the sample submitted.



Photo: Flickr/© "Flooded Paddock," byfreebird4, used under CC BY-NC 2.0. Cropped from original.

CSU VDL in the Field: Case Study

Varied Weather, Varied Bacteriology

A recent CSU Veterinary Diagnostic Lab case serves as a reminder that even minor changes in weather can influence the growth of bacteria, alter bacteria/animal interactions and potentially impact animal health.

The heavy September rainfall flooded some sewage-treatment plants, raising concerns about increased coliform counts in water supplies. Because moisture is often the limiting ingredient for microbial growth, bacteria and fungi that have remained dormant during drought flourish in soils after rain, particularly spore-formers such as *Bacillus anthracis*, the causative agent of anthrax, and species of *Clostridium*.

Two horses aged 30 years or older developed severe pneumonia with nasal hemorrhage (epistaxis) 12 and 14 days after the end of several days of rain. Both were euthanized due to a poor prognosis. On necropsy, blood was found in the trachea, and the lungs appeared mottled. Fresh lung was submitted for Anthrax PCR, equine herpesviruses 1 and 4 PCR, influenza A virus RT-PCR and aerobic bacteriology culture. The lung was negative for the PCRs, but a heavy growth of *Klebsiella pneumoniae* was obtained in pure culture. An antimicrobial susceptibility panel showed the bacteria were susceptible to a wide range of antibiotics.

K. pneumonia is a Gram negative rod with a large capsule that gives the colonies a distinctive appearance. Normally found in the intestinal tract of humans and other animals, the bacterium is an opportunist, taking advantage of the host's impaired defenses. *K. pneumonia* causes foal pneumonia and is found in the repro-

—Hana Van Campen, DVM, PhD, DACVM, CSU VDL Virology Section Head; J.D. Leclair, DVM, JD Leclair Equine Medicine and Surgery; Doreene Hyatt, PhD, CSU VDL Bacteriology Section Head; and Denise Bolte, CSU VDL Laboratory Technician

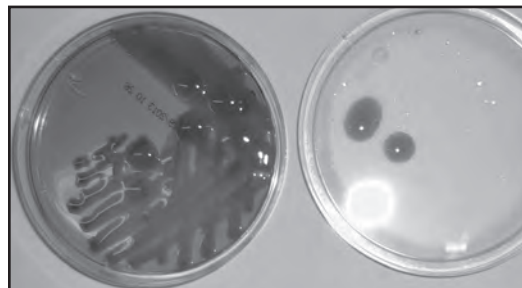
ductive tracts of mares with metritis and the prepuce of stallions. It has rarely been reported as a cause of pneumonia in adult horses. *Klebsiella* is also one of the most common causes of dairy bovine mastitis in some parts of the United States. In a five-month study in 10 herds across New York and Massachusetts, fecal samples collected from 100 healthy dairy cows found more than 80 percent positive for *K. pneumoniae*.¹

K. pneumoniae is also a concern in human medicine because of the possibility of nosocomial spread to persons with weakened immune systems. It contributes to nosocomial pneumonia, septicemia, urinary-tract infections, wound infections, intensive-care unit infections and neonatal septicemias.² Of particular concern in hospitals is the occurrence of multi-antibiotic-resistant *K. pneumonia*.

The affected horses in this case had lived on the same premises and pasture for 19 years. No new horses had been introduced to the premises, nor had changes in feed or other management been made. The owner was concerned about possible sources of bacteria in runoff from an adjacent dairy lagoon into a ditch at the end of the pasture, and from a seepage/slough at the bottom of the pasture. Water samples were obtained from two sections of the slough and from the ditch. Surface water was sampled from the area of the pasture with new grass growth, from two areas of the leachfield for the house that extended into the paddock and from an additional two areas of the pasture. All samples contained many coliform bacteria. Two *Klebsiella* isolates were found, one from the leach field and one from the slough. However, each isolate appeared to be a distinct species, *K. ozunae* and *K. oxytoca*. The same *Klebsiella* that caused pneumonia in this case was not cultured from environmental samples, so the source of infection remains a mystery. ▲

REFERENCES

- 1 Munoz MA, Ahlström C, Rauch BJ, Zadoks RN. Fecal shedding of *Klebsiella pneumoniae* by dairy cows. *J Dairy Sci.* 2006 Sep;89(9):3425-30.
- 2 Janda JM, Abbott SL. The Genera *Klebsiella* and *Raoultella*. In: Janda JM, Abbott SL, eds. *The Enterobacteria* 2nd ed. Washington: ASM Press; 2006:115-129.



K. pneumonia's large capsule gives the Gram negative rod colonies their distinctive appearance.



Introducing: Zoo Corner

Endocarditis in a Gibbon

— Sushan Han, DVM, PhD, DACVP, CSU VDL Pathologist

A 16.5 year-old female golden-cheeked gibbon (*Hylobates gabriellae gabriellae*) presented with intermittent and progressive lethargy, anorexia and constipation of three weeks duration despite supportive care. Blood work



showed a neutrophilic leukocytosis and mild anemia with no radiographic or abdominal ultrasound abnormalities. She was unresponsive to systemic antibiotic therapy and progressed to develop neurological signs that included intermittent disuse of the left hand and drooling from the left side of the mouth. Within 48 hours she presented moribund with severe pulmonary edema and hemorrhage. Necropsy revealed:

- Vegetative endocarditis of the left atrioventricular valve with diffuse and severe pulmonary edema and hemorrhage and bilateral epistaxis.
- Widely disseminated foci of hemorrhage and necrosis in most viscera, including an extensive area of malacia and hemorrhage in the right temporal lobe of the cerebrum (4x1.5x1.3 cm), effacing most of the right thalamus with extension rostrally and caudally into the frontal and occipital lobes, respectively.
- Multiple acute and chronic infarctions of both renal

cortices consistent with vascular thrombosis and moderate amounts of serosanguinous ascites.

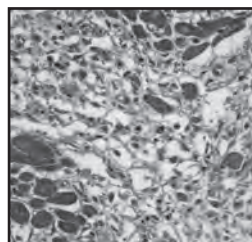
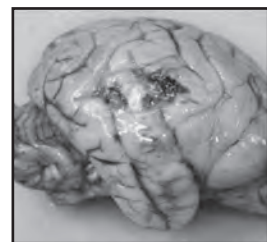
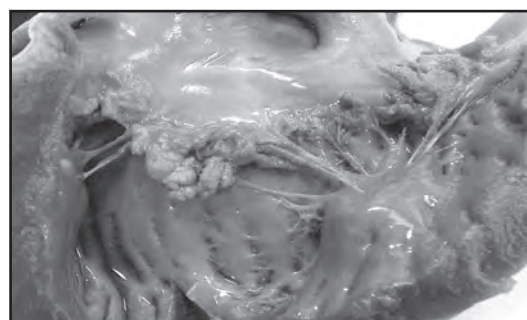
Histologically, vegetative endocarditis was associated with large coalescing colonies of gram positive cocci and suppurative and necrotizing endocarditis and myocarditis. Aerobic cultures were positive for *Staphylococcus aureus*. Interestingly, all heart walls had large, random and vasculocentric foci of myocardiocyte drop-out and replacement by fibroplasia with cardiac histiocytes and scattered hemosiderophages. Also, suppurative and hemorrhagic encephalitis appeared consistent with septic embolism. Suppurative tubular nephritis likely indicated ascending urinary tract infection.

Valvular endocarditis with Gram-positive cocci bacteria caused the death. The literature documents well *S. aureus* endocarditis in primates.^{1,2} Sources include chronic wounds, chronic inflammation or infections and indwelling catheters, with some cases occurring spontaneously.²

In this case, we didn't definitively determine a cause of endocarditis, but suppurative tubulonephritis may be a potential source of septicemia. Necrotizing and suppurative encephalitis and renal infarctions are consistent with embolic showering from valvular endocarditis. Extensive acute pulmonary hemorrhage and edema is likely caused by terminal disseminated intravascular coagulation from septicemia and endotoxic shock syndrome.

Myocardial degeneration and fibrosis is an interesting lesion. Lesions may be related to endocarditis via vascular compromise with secondary myocardial infarction; however, most lesions have established fibroplasia, which would suggest a chronicity of three or more weeks and may pre-date endocarditis. Fibrosing cardiomyopathy has been described in many species of nonhuman primate including the gibbon.³ Causes include spontaneous or idiopathic myocardiocyte degeneration, virus associated myocarditis (influenza, encephalomyocarditis virus, Coxsackie B virus, and others), myocardial infarction secondary to atherosclerosis, and nutritional myodegeneration (hypovitaminosis E).^{1,4}

The clinical significance of myocardial degeneration in this case is not determined though it can be a cause of chronic cardiovascular insufficiency and sudden fatal arrhythmia in the great and lesser ape. ▲



(Clockwise from top)

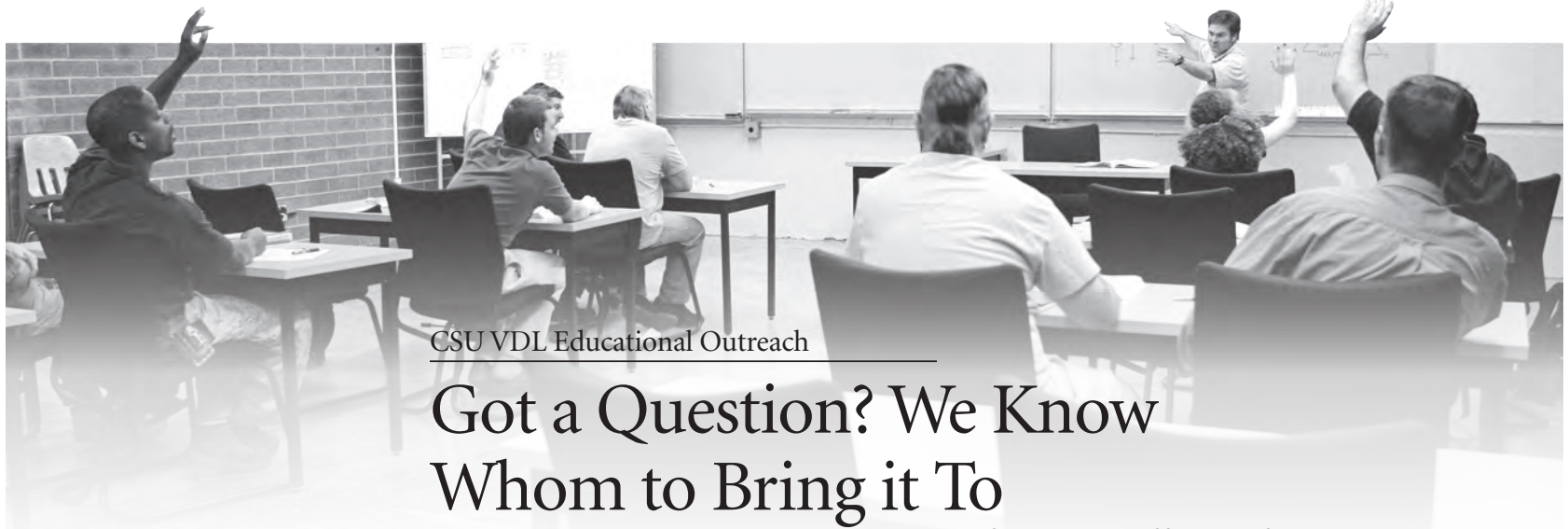- Vegetative endocarditis of the mitral valve.
- Photomicrograph of myocardial fibrosis throughout the heart walls.
- Hemorrhagic and necrotizing encephalitis of the right cerebral hemisphere.

REFERENCES

1. Chamanza R, Parry NMA, Rogerson P, Nicol JR, Bradley AE. Spontaneous Lesions of the Cardiovascular System in Purpose-Bred Laboratory Nonhuman Primates. *Toxicol Pathol.* 2006;34(4):357-63.
2. Ayers KM, Jones SR. The Cardiovascular System. In: Benirschke K, Garner FM, Jones TC, eds. *Pathology of Laboratory Animals* Vol. 1. New York: Springer-Verlag; 1978:1-56.
3. Borkowski R, Taylor TG, Rush J. Cerebral infarction and myocardial fibrosis in a white-handed gibbon (*Hylobates lar*). *J Zoo Wildl Med.* 2000 Mar;31(1):65-70.
4. Lowenstine LJ. A Primer of Primate Pathology: Lesions and Nonlesions. *Toxicol Pathol.* 2003 Jan-Feb;31 Suppl:92-102.

ACKNOWLEDGEMENTS

Thanks to Betsy Stringer and Scott Larsen for providing this case and supplying the detailed history and clinical findings



CSU VDL Educational Outreach

Got a Question? We Know Whom to Bring it To

— Charlie Davis, DVM, CSU VDL Lab Coordinator

Much as today's practitioner of veterinary medicine has learned from the new economics of the trade, we in the Veterinary Diagnostic Lab System must look for opportunities to add value to our traditional services by translating the knowledge and intellectual capital we have at our disposal into value for our end customers. That's a succinct statement of the purpose of the VDL's Lab Coordinator position.

The Lab Coordinator offers clients and stakeholders access to a key point person with the system, someone they can talk to personally, and someone who can field their questions and direct them to where they need to go to get answers. When coupled with the depth of knowledge represented by the entire CSU system, it's a customer service that many diagnostic labs may still be missing.

With that said, it's important for clients to consider that questions need not be limited just to diagnostic issues anymore. VDL Director Barb Powers and others in the system purposely set out several years ago, when they created the lab coordinator position, to put themselves in the chair of the working practitioner, the ranch client, the small-animal clinic owner. They asked: How can we bridge all of the potential disconnects between the day-to-day information needs of those groups and the wealth of resources here at our fingertips?

Take food-animal practice, for instance, specifically cattle. When a cow/calf producer reaches us with a specific question about, say, using PCR to evaluate his herd's BVD status, that question may be just the proverbial tip of the iceberg about numerous underlying questions regarding managing the disease to improve his profitability. With that understanding, we can then pull assistance from the clinical specialists, nutritionists, physiologists, geneticists, population medicine and herd-health specialists in the College of Veterinary Medicine and Biomedical Sciences, the Animal Science department, and the extension arm of those schools to answer questions that may not have even occurred to them.

THEORY IN PRACTICE

What does that kind of outreach look like in practice? Here are some recent activities of the lab coordinator:

1 We organized a conference call in May for a rancher from southern Colorado who has been experiencing a variety of issues in his ranching operation with respect to cattle health problems. Participants in that call included his attending veterinarian along with doctors from the veterinary teaching hospital and diagnosticians from each section of the diagnostic lab—virology, parasitology, pathology and toxicology—as well as director and pathology specialist Powers. In addition, three senior students with interest in food-animal medicine were invited to attend this unique real-world learning experience.

2 I traveled to a sheep feedlot in June with Steve LeValley, the CSU Animal Science department's sheep specialist. This visit demonstrates our lab's ability to bring in expertise from other CSU colleges to provide consultation as well as gain some insight into management issues and factors that may be in play. In this case, it related to significant numbers of positive Listeriosis cultures by the VDL since January.

3 I have had interaction with a number of veterinarians, lab clients and producers of late with questions including a query from the small animal side with respect to heartworm incidence and testing and also *Leptospira* testing numbers for dogs. That outreach included putting a metro clinic practitioner in touch with several experts within our system to help him develop an in-clinic brochure to advise his clients on key questions like vaccination protocols and heartworm testing advice.

Other issues have concerned equine rabies incidence, livestock drought-related questions and issues related to recent flooding. ▲

Spur any ideas or questions about how you get more value out of the Diagnostic Lab? Call Charlie Davis (970) 297-0370 or email Charlie.Davis@colostate.edu

Guardians of Public Health

Salmonella in Poultry Exhibits at Colorado Agricultural Fairs

Salmonella infects an estimated 1.4 million people in the United States annually, causing an estimated 400 deaths. In 2011, 522 human cases of *Salmonella* infection were reported in Colorado. Transmission typically occurs through consumption of contaminated food products or contact with infected animals, including poultry. One study predicted 127,000 infections annually result from contact with *Salmonella*-infected animals.

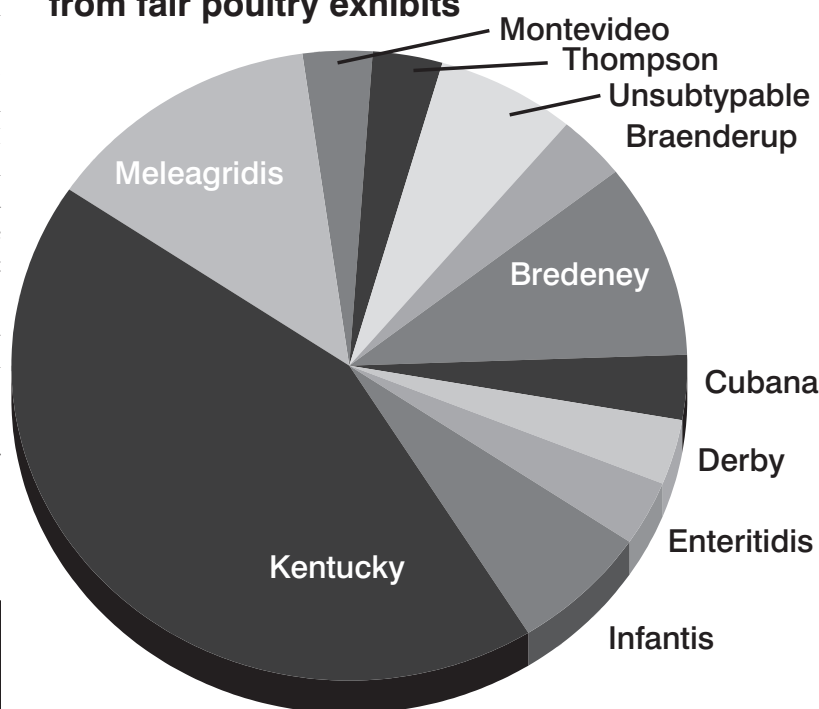
People are at risk of zoonotic infection with *Salmonella* from contact with animals in public settings, such as agricultural fairs. Poultry fanciers and breeders, 4-H participants and the general public have contact with live poultry at state and county fairs across the United States. The objective of this study was to evaluate the level of *Salmonella* contamination in the environment in poultry exhibits at these fairs.

We collected samples from cages, feed, floors and tables in the exhibit and cultured for *Salmonella* from 11 Colorado agricultural fairs. Each fair had attendance of between 25,000 and 85,000 people. We found:

- At least one environmental sample was positive for *Salmonella* in 10 of the 11 fairs, or 91 percent.
- *Salmonella* was isolated from 28 of 55 environ-

— Kristy Pablonia, DVM, DACVM, CSU VDL Avian Diagnostics and BSL3 Operations Section Head; and Kyran Cadmus, DVM, MPH, Avian Diagnostics Research Associate

Salmonella serotypes isolated from fair poultry exhibits



mental samples, or 50.9 percent of samples. The most common positive sample type was waterfowl litter, with eight of 11 fairs positive; followed by tables, at seven; chicken and turkey litter, at 6; floors, at 6; and feed, at 1 positive fair.

- Eleven different serotypes were detected. All but one are commonly associated with U.S. poultry, and nine of the 11 have been associated with human illness through either food consumption or environmental or animal contact.

Our results demonstrate that environmental surfaces at fairs could act as a route of *Salmonella* transmission to poultry owners and the general public. Agricultural fairs should consider instituting policies and practices to improve hygiene, mitigate risks of zoonotic Salmonellosis and educate participants and the public about these risks.

Pablonia KL, Cadmus KJ, Lingus TM, Bolte DS, Russell MM, Van Metre DC, Erdman MM. Environmental *Salmonella* in Agricultural Fair Poultry Exhibits in Colorado. *Zoonoses Public Health*. 2013 in press.





Diagnostic Sample Quality Assurance

Five Tips to Get Better, Faster Results

With some 300 to 400 accessions or cases—not just samples—arriving daily, incomplete or inaccurate test request forms can create significant issues. Often, those issues result in receiving personnel having to personally contact the requestor to find out what exactly was being requested. Submission forms that arrive in our system without full information

— Charlie Davis, DVM, CSU VDL Lab Coordinator

can hamper our goal to provide accurate and timely results, timely reporting and correct billing. Won't you take a few moments of time to make sure you're not neglecting these five simple steps to help us serve you better by getting us off to a better start? ▲

1 SPECIFY TEST TYPE. Numerous tests may be available for any disease. If the particular test you want isn't marked on the submission form, our receiving personnel will have to follow up to complete the form, possibly delaying the timing of test completion and final reporting. If you have a question about which test is best, call us first.

2 DOUBLE CHECK ACCURACY. It goes without saying that the type of sample, proper collection methods, the method of preparation and timeliness of delivery to the lab with a complete and accurate submission or request form dictates the accuracy, relevancy and timeliness of results presented. Doublecheck your contact info, as well.

3 GIVE US A HISTORY. One of the most lacking inclusions in submission forms is a decent clinical history. Granted, sometimes clinical history may be of little importance to the lab. However, the vast majority of the time, clinical history is extremely important. A good clinical history allows judgment on a case prognosis or reflects results that may or may not be as expected. For example, bacteriology culture results are commonly skewed by antimicrobial administration. And vaccination history obviously tells a great deal when evaluating titer levels as disease contributor. Parasitic treatment timing not mentioned in a history may very well affect a reported result.

4 BE BRIEF, BUT COMPLETE. Clinical history provided on submission forms need not be lengthy to be valuable. Rather, completeness and accuracy with respect to relevant information about the case, summarized briefly, is valuable. Presentation of good clinical history benefits the personnel in the laboratory when asked for diagnostic interpretation, prognoses or opinions. In the end, the real benefactor is the person submitting the sample and, ultimately, the client.

5 LET OTHERS KNOW. If the veterinarian delegates the job of completing submission forms, technicians, assistants and perhaps students that are involved should be instructed in completing the information.

GET YOUR RESULTS ANY WAY YOU WANT THEM

Our lab's web-based improvements have made it easier than ever to get your test results where, when and how you want. Don't forget we offer numerous avenues, digital and traditional, to get your results any way you want:

■ On-line, via password-protected portal on our website. Create your own personal account, and you can view your results at any time, 24/7.

■ Hard copy, mailed to you.

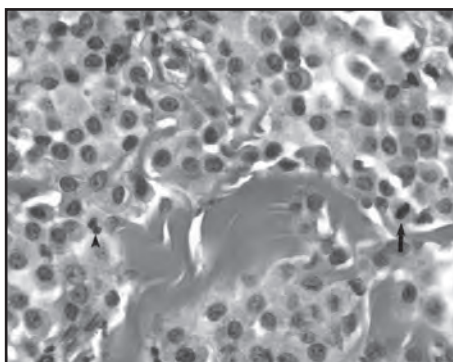
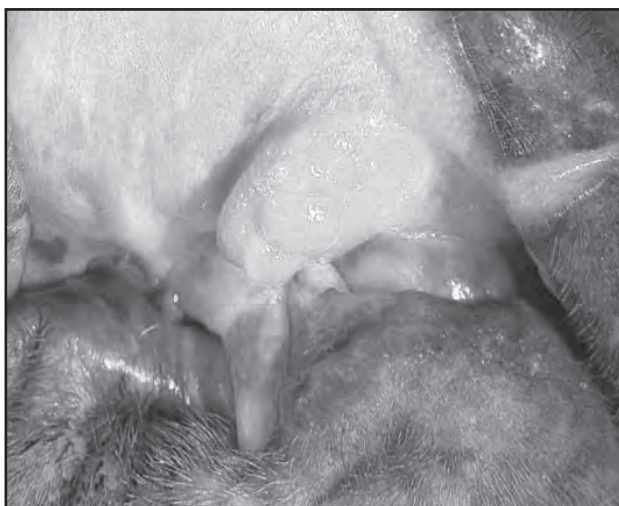
■ Faxed hard copy.

■ Electronic file delivered by e-mail

Let us know how you wish to receive your results. Call (970) 297-1281 or E-mail us at www.dlab.colostate.edu to tell us your personal preference.

Questions?

Call Charlie Davis
(970) 297-0370 or
email him at
Charlie.Davis@colostate.edu



Oral mass lesion (left) identified on a 10-year-old Shar-Pei during a routine physical examination. Photomicrograph (top) of a section of the oral mass.

CSU VDL in the Field: Case Study

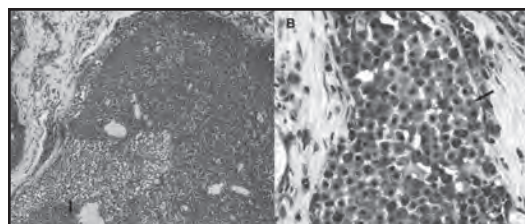
Oral Canine Mast Cell Tumor

A 10-year-old spayed female Shar-Pei cross was referred for an oral mass lesion detected during a routine exam. There was no associated clinical illness.

Clinical and Gross Findings. An oral mass was removed by partial maxillectomy from the rostral buccal mucosa in the deep portion of the upper vestibule located 1 to 2 cm off midline to the right and adjacent to the second and third right incisors. Palpable enlargement of two right submandibular lymph nodes was evident. The mass was 1.5 by 1 by 0.5 cm, broad based, slightly firm and multifocally ulcerated with an irregular lobulated surface.

On cut section, the oral mass was homogeneously pale tan in coloration and had poor demarcation, blending with the deep and adjacent submucosal connective tissue. The submandibular lymph nodes were up to two times the typical size of healthy dogs' but retained normal anatomic architecture on cut surface with visible boundaries between cortex and medulla. No mass lesions were grossly identified in the lymph nodes.

Findings. The oral mass was an infiltrative and poorly demarcated mass of neoplastic round cells that infiltrated and effaced the submucosa and extended to an overlying multifocally ulcerated mucosal epithelial surface.



Toluidine blue stained lymph node tissue revealed numerous metachromatic granules in the described cells' cytoplasm.

— Kristy Pabilonia, DVM, DACVM, CSU VDL Avian Diagnostics and BSL3 Operations Section Head; Brendan K. Podell, DVM, DACVP; CSU Microbiology, Immunology and Pathology Research Fellow; and Barbara Powers, DVM, PhD, DACVP, CSU VDL Director

Neoplastic cells separated and individualized collagen bundles and were surrounded by abundant edema fluid with numerous infiltrating eosinophils. The neoplastic cells were round with distinct borders and abundant cytoplasm and contained numerous faintly discernible, punctate, basophilic granules. The nuclei were round to oval with coarse clumped chromatin and indistinct nucleoli. There were mild variations in nuclear size and shape; 5 mitotic figures were detected in ten 400X fields.

In the submandibular lymph node tissue, discrete round cells that were individualized or formed rare aggregates frequently occupied the subcapsular and medullary sinuses and were rarely incorporated into adjacent lymphoid follicles. The cells appeared similar to those observed in the primary oral mass. There was no distinct effacement of the lymph node architecture. Stained lymph node tissue sections revealed numerous metachromatic granules in the cytoplasm of these cells.

Diagnosis and Case Summary. A relatively rare mast cell tumor of the oral mucosa with submandibular lymph node metastasis. This case highlights the prognostic implications of MCT location and its impact on histologic grading. ▲

Follow-Up Note. The dog in this case was treated with surgery and three rounds of chemotherapy and is still alive more than two years after the diagnosis was made.

Pabilonia KL, Podell BK, Powers BE. Mast cell tumor (MCT) of the oral mucosa with submandibular lymph node metastasis in a dog. *J Am Vet Med Assoc.* 2013 Sep 15;243(6):795-7.



CSU VDL in the Field: Disease Updates

Non-Neoplastic Lesions Of Equine Skin In The Central United States



This study was funded through Cappy's Equine Dermatology Research Fund, established in honor of Mary Lou Lane's horse, Cappy, to help support research related to diagnosing equine dermatology problems. For details, visit advancing.colostate.edu/cappysfund

Schaffer PA, Wobeser B, Dennis MM, Duncan CG. Non-neoplastic lesions of equine skin in the central United States and Canada: a retrospective study. *Can Vet J.* 2013 Mar;54(3):262-6.

Geography, climate, season, pathogens and vectors, as well as host-factors can all affect non-neoplastic skin disease, and in veterinary dermatology, several well-known geographic and seasonal trends exist. While some non-neoplastic equine dermatologic conditions have been reviewed on the east and northwestern coasts, no data are available regarding types and distributions in horses of the central United States or central Canada, a unique geographic environment distinct from both those areas. Our study was designed to retrospectively review a decade of skin biopsies from non-neoplastic equine skin conditions submitted to CSU's Veterinary Diagnostic Lab in Fort Collins, as well as the University of Saskatchewan's Prairie Diagnostic Services. We found:

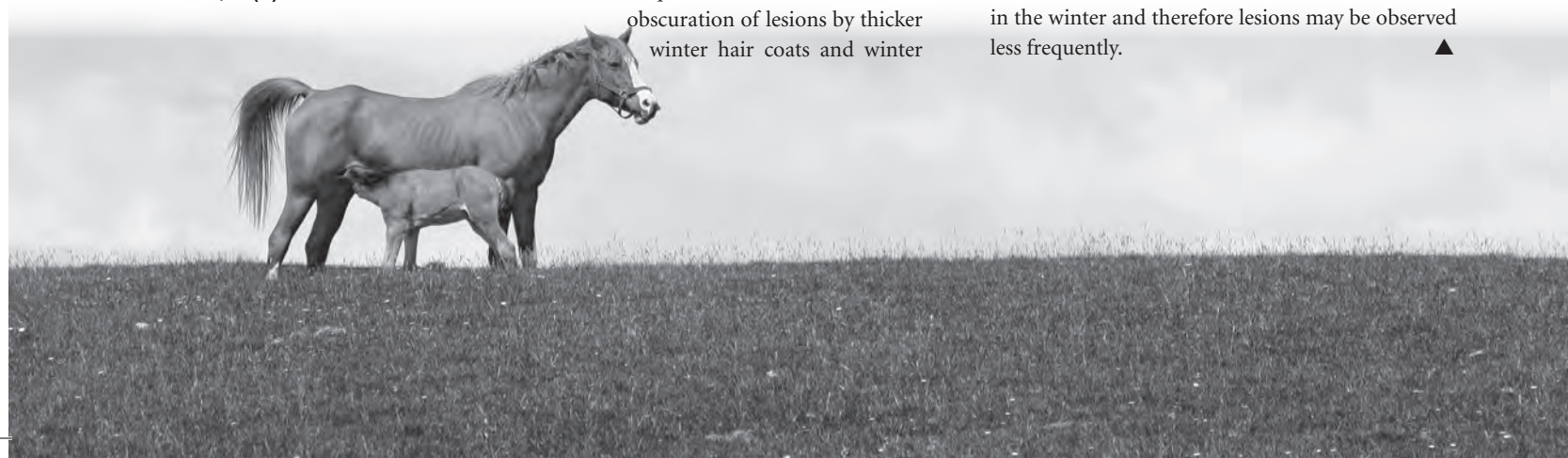
■ Non-neoplastic lesions comprised nearly 35 percent of total equine cutaneous biopsies submitted to CSU and PDS in the 10-year period evaluated. That incidence contrasts with 88 percent of total submissions received by Cornell University in a 2001 study. Non-neoplastic lesions could be more common in the Northeast; however, it may be higher numbers of equine practitioners selectively submit biopsies there. A 2005 Oregon State study found 8.7 percent of submissions to that school were non-neoplastic nodular and proliferative lesions. Again, it is difficult to compare our data to those, since that study specifically evaluated only nodular and proliferative non-neoplastic lesions.

■ Overall, skin biopsy submissions were more common in spring, summer, and fall than in winter. All types of inflammatory lesions were more common in spring, summer, and fall relative to winter, but eosinophilic biopsies appeared to have the most striking seasonal trend. Several factors may influence that variability: Cyclical presence of biting insects such as mosquitoes and culicoides, and obscuration of lesions by thicker winter hair coats and winter

— Paula Schaffer, DVM, PhD, CSU VDL Postdoctoral Fellow, and Colleen Duncan, DVM, MSc/PhD/DACVP/DACVPM, CSU VDL Pathologist

Etiology	CSU	PDS	Total/%
Unknown	563	347	910/50.8%
Eosinophilic syndromes	359	158	517/28.8%
Eosinophilic	209	91	300/16.7%
Eosinophilic granuloma	150	67	217/12.1%
Bacterial	49	12	61/3.4%
Benign cyst	51	8	59/3.3%
Autoimmune suspect	22	34	56/3.1%
Fungal (non-dermatophyte)	34	10	44/2.5%
Granulation tissue	21	21	42/2.3%
Dermatophytosis	11	25	36/2.0%
Suspect hypersensitivity	22	5	27/1.5%
Foreign material	4	6	10/0.6%
Parasite	5	3	8/<0.5%
Solar elastosis	5	0	5/<0.5%
Photosensitivity suspect	0	4	4/<0.5%
MEED suspect	0	2	2/<0.5%
Calcinosis circumscripta	0	2	2/<0.5%
Amyloid	0	1	1/<0.5%

blankets. In addition, riding activity may be lessened in the winter and therefore lesions may be observed less frequently. ▲





Food Animal Production Medicine

Bovine Trich Submissions Update

Collaboration between the Colorado State Veterinarian, the Colorado Department of Agriculture Rocky Mountain Regional Animal Health Laboratory and CSU's Veterinary Diagnostic Laboratory system has resulted in the following updated Colorado bovine trichomoniasis sample submission recommendations:

ACCEPTABLE CULTURE SAMPLES

InPouchTF – received within 48 hours of collection.

Expired InPouchTF – expired pouches will be accepted on a case by case basis after consultation with the State Veterinarian. If approved for testing by the State Veterinarian, it must arrive at the laboratory within 24 hours of collection.

Lactated Ringers Solution – received within 24 hours (hand carried, UPS, FedEx or other courier is acceptable) of collection. Lactated Ringers Solution is to be used for emergency situations only. If LRS is used as the transport media, the lab will transfer the sample to a chosen growth media and the veterinarian will be charged for that media.

Other Growth Media (i.e. Diamonds) – received within 48 hours of collection.

ACCEPTABLE PCR SAMPLES

Acceptable samples:

InPouchTF or TFTransit Tube – received within 72 hours of collection (samples received after 72 hours of collection will be accepted on a case by case basis after consultation with the State Veterinarian).

Expired InPouchTF or TFTransit Tube – will be accepted on a case by case basis after consultation with the State Veterinarian. If approved for testing by the State Veterinarian, it must arrive at the laboratory within 24 hours of collection.

Lactated Ringers Solution – received within 24

— Charlie Davis, DVM, CSU VDL Lab Coordinator

hours (hand carried, UPS, FedEx or other courier is acceptable) of collection. Lactated Ringers Solution is to be used for emergency situations only. If LRS is used as the transport media, the lab will transfer the sample to a chosen growth media and the veterinarian will be charged for that media.

Other Growth Media (i.e. Diamonds) – received within 72 hours of collection.

Once your chosen lab receives the samples, they will be handled dependent on that laboratory's protocol for running the desired test.

The Colorado State Veterinarian prefers either InPouchTF or TFTransit Tubes be used for submission of trichomoniasis samples. Realizing that situations may occur where outdated sample submission products are all that is on hand at a time when collections need be made or samples for PCR testing arriving after 72 hours of collection, the state veterinarian has agreed that consultation with him on a case by case basis will take place before determination is made on acceptance of the samples. In addition, in order to work with veterinarians in the field, should they be caught without InPouchTF or TFTransit Tube media, acceptance of samples placed in Lactated Ringers Solution or other media such as Diamonds media will be accepted but use of those media is not to be the norm.

Bottom line, properly collected trichomoniasis samples preferably placed in correctly dated InpouchTF or TFTransit Tube media, handled correctly with respect to temperature and packaging, delivered to the laboratory of choice within the proper timelines of the test desired will allow for results that are accurate. ▲

BOVINE TRICH TESTING AT CSU SAMPLES

■ Prepuccal scrapings collected by a certified veterinarian

COST

■ PCR \$25

Photo: Flickr/© "Bull with cow at Penn State farm," Patrick Mansell/Penn State News, used under CC BY-NC-ND 2.0. Cropped from original.



CSU VDL In Press

A Roundup of VDL Faculty Research



Dirsmith K, VanDalen K, Fry T, Charles B, VerCauteren K, Duncan C. Leptospirosis in fox squirrels (*Sciurus niger*) of Larimer County, Colorado, USA. *J Wildl Dis.* 2013 Jul;49(3):641-5.

Leptospira interrogans is typically maintained within a geographic region by colonizing renal tubules of carrier animals which then shed the bacterium into the environment via urine. Because in many areas the carrier species are unknown, this study assessed whether it was present in fox squirrels (*Sciurus niger*) in Larimer County, Colo. The research team which included VDL Honors Undergraduate Research Scholar Katherine Dirsmith and VDL Pathologist Colleen Duncan, examined 22 squirrels that had been live-trapped in late 2011 for another study and showing no clinical disease at euthanasia. On gross examination, they observed significant renal lesions in 27 percent of them. Histologically, affected animals had severe neutrophilic tubulitis with interstitial nephritis. After conducting immunohistochemistry on the kidneys of all animals, they found 45 percent were positive for *L. interrogans*, with varying severity of infection. The same 10 squirrels were serologically posi-

tive for *Leptospira*. These results suggest *L. interrogans* is present in fox squirrels in Larimer County, and the unexpectedly high prevalence of disease and antibody-positive animals may be important in the epidemiology of leptospirosis in the region. Leptospirosis is being identified in Colorado at an increasing frequency; between 2005 and 2008, 85 canine cases were suspected and 15 confirmed in the county. Results of this study suggest squirrels may present a risk to humans or other mammals in Larimer County, but further investigation is needed to better understand the spread of leptospirosis at the urban/wildlife interface.

Woolums AR, Berghaus RD, Smith DR, White BJ, Engelken TJ, Irsik MB, Matlick DK, Jones AL, Ellis RW, Smith IJ, Mason GL, Waggoner ER. Producer survey of herd-level risk factors for nursing beef calf respiratory disease. *J Am Vet Med Assoc.* 2013 Aug 15;243(4):538-47.


CSU VDL Pathologist Gary Mason worked with colleagues across the country on this population-based cross-sectional survey of 2,600 U.S. cow/calf producers in three Eastern and three Plains states to identify herd characteristics that might influence Bovine Respiratory Disease detection and treatment in young calves.

By surveying producers on their practices, the study determined, among other findings, the following:

- BRD had been detected in at least one calf in 21 percent of all operations. Within those affected operations, at least one calf was treated and one calf died because of BRD in 89.2 percent and 46.4 percent of operations, respectively.
- Detection of BRD in calves was significantly associated with large herd size, detection of BRD in cows, and diarrhea in calves.
- Length of the calving season was associated with BRD incidence in calves in Plains states but not Eastern states.
- Cumulative incidence of BRD treatment was negatively associated with large herd size and examination of cows to detect pregnancy. It was positively associated with calving during the winter, introduction of calves from an outside source, offering supplemental feed to calves, and use of an estrous cycle synchronization program for cows.

Of course, the authors caution, the practices they found to be associated with BRD cannot be assumed to be causative, some of them may be. The study offers clues as to need for further investigation.

Photo: Flickr/© "Fox squirrel," Matthew Paulson, used under CC BY-NC-ND 2.0.





Clarke L, Simon A, Ehrhart EJ, Mulick J, Charles B, Powers B, Duncan C. Histologic Characteristics and KIT Staining Patterns of Equine Cutaneous Mast Cell Tumors. Vet Pathol. 2013 In Press.

The proto-oncogene c-KIT has been implicated as an important prognostic factor in canine cutaneous mast cell tumors and associated with poor clinical outcomes. Horses also get mast cell tumors, but much less is known about prognostic factors in this species. This study selected a subset of 72 mast cell tumors from 92 equine skin tumors diagnosed at CSU's Veterinary Diagnostic Lab between 2000 and 2010. Several members of the lab faculty reviewed the tissue sections for histologic features, including demarcation of the lesion, the estimated percentage of mast cells in the lesion, mast cell pattern, cell morphology, granularity, differentiation, mitotic figures and completeness of excision. A single slide was selected for KIT IHC based on the quantity and quality of the paraffin-embedded tissues using anti-human KIT antibody. Tumors were classified into one of three groups according to KIT staining patterns described in the dog. A clinical follow-up survey was faxed to the submitting veterinarian requesting information, including patient signalment, size, number, and anatomic location of the lesions, associated clinical disease, abnormal complete blood count findings, completeness of surgical excision, postoperative healing, adjunctive therapy, whether there was local recurrence or other mast cell tumors on the horse following the primary excision, and status of the horse at the time of last checkup.

Basic signalment or clinical follow-up data were available for 62 of the horses. The study found most tumors were well differentiated with low mitotic rates (96 percent), and aberrant KIT staining patterns, as described in dogs, were uncommonly identified (12 percent). Associated clinical disease was uncommon and no tumors exhibited malignant behavior. Overall, KIT staining pattern and histologic features were not associated with poor clinical outcome or abnormal tumor behavior.

Barrera JS, Bernard F, Ehrhart EJ, Withrow SJ, Monnet E. Evaluation of risk factors for outcome associated with adrenal gland tumors with or without invasion of the caudal vena cava and treated via adrenalectomy in dogs: 86 cases (1993-2009). J Am Vet Med Assoc. 2013 Jun 15;242(12):1715-21.

VDL Pathologist E. J. Ehrhart was involved in this retrospective study of 86 dogs that underwent adrenalectomy



for treatment of adrenal gland tumors from 1993 to 2009. Data collected included signalment, clinical signs, diagnostic test findings, pre-surgical treatments, findings at surgery including additional procedures performed and extent of caudal vena caval invasion (local invasion [caudal to the hepatic portion of the vena cava] or extensive invasion [cranial to the hepatic portion of the vena cava]), procedures performed during surgery, histopathologic diagnosis, perioperative complications, follow-up data, and necropsy findings. The study's results showed that of the 86 animals, 14 had adenomas, 45 had adrenocortical carcinomas, and 27 had pheochromocytomas. Fourteen dogs had invasion of the caudal vena cava; of these tumors, 7 were locally invasive and 7 were extensively invasive. Risk factors for death within 14 days following surgery, included

- Vena caval invasion and extent of invasion. Multivariate analysis revealed extensive invasion was the most important risk factor. Invasion of the caudal vena cava, particularly tumor thrombus extension beyond the hepatic hilus, was associated with a higher postoperative mortality rate, but did not affect long-term prognosis
- Pheochromocytoma
- Intraoperative transfusion
- Post-operative factors, including disseminated intravascular coagulation, pancreatitis, hypotension, hypoxemia and renal failure.

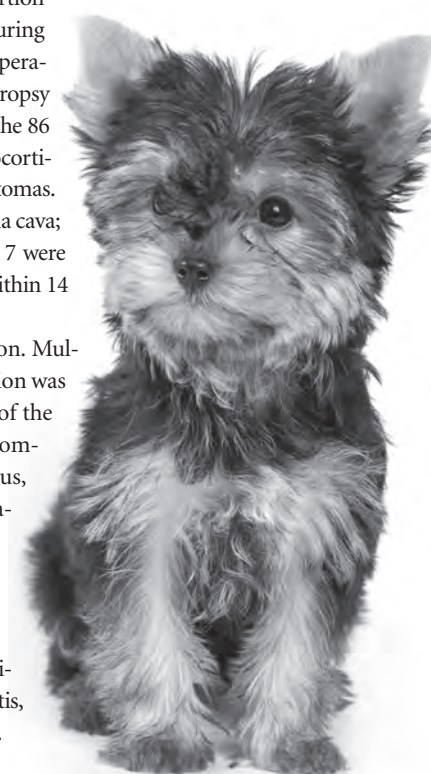




Photo: Flickr/© "Northern Fur Seal," Ocean Networks Canada. Used under CC BY-NC-SA 2.0.



Minor C, Kersh GJ, Gelatt T, Kondas AV, Pablonia KL, Weller CB, Dickerson BR, Duncan CG. *Coxiella burnetii* in northern fur seals and Steller sea lions of Alaska. *J Wildl Dis.* 2013 Apr;49(2):441-6.

VDL faculty members Kristy Pablonia and Colleen Duncan and Lab Technician Christina Weller worked with the Center for Disease Control in Atlanta to test archived sera and vaginal swabs from 236 northern fur seals and 72 Steller sea lions sampled in Alaska for exposure to or infection by *C. burnetii*, a zoonotic bacterium recently identified in several marine mammal species on the North American Pacific coast. They found *C. burnetii* is more prevalent within these populations than previously known:

- The 69 percent antibody prevalence in the seal samples from 2009 and 2011 was significantly higher than the 49 percent found in 1994, suggesting the pathogen may be increasingly common or that there is marked temporal variation within the vulnerable seal population.
- The antibody prevalence of sea lion samples from 2007 to 2011 was 59 percent, suggesting the pathogen may be significant in the endangered sea lion population.
- All seal vaginal swabs were negative, despite a high percent antibody prevalence in the matched sera.

Monello RJ, Powers JG, Hobbs NT, Spraker TR, O'Rourke KI, Wild MA. Efficacy of antemortem rectal biopsies to diagnose and estimate prevalence of chronic wasting disease in free-ranging cow elk (*Cervus elaphus nelsoni*). *J Wildl Dis.* 2013 Apr;49(2):270-8.

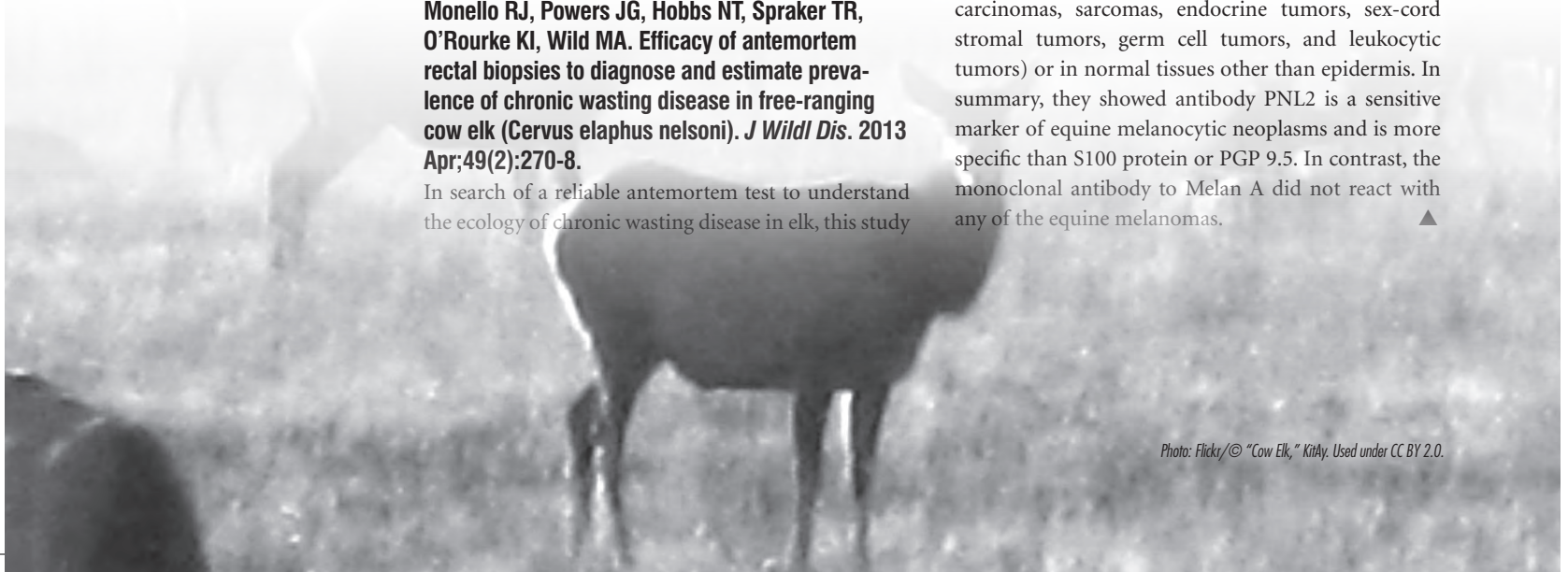In search of a reliable antemortem test to understand the ecology of chronic wasting disease in elk, this study

involving VDL Pathologist Terry Spraker measured the ability of antemortem biopsy samples from the rectal mucosa to detect the abnormal prion protein associated with the disease. They sampled 136 adult female elk in winter of 2007-2008, euthanizing those showing biopsy samples positive for the target CWD prion by immunohistochemistry. The obex and retropharyngeal lymph nodes were then examined with IHC. They resampled, euthanized, and necropsied 20, 25, and 34 of the remaining study elk in each of three following winters, respectively. Sensitivity of rectal biopsy samples increased in an asymptotic fashion with follicle count and was maximized at 85 percent in the beginning of the study, when a greater proportion of elk were in a detectable stage of prion infection. Maximum sensitivity fell to 72 percent when recently infected elk that were initially negative were included. The study shows rectal biopsies can provide a useful research tool for CWD in elk populations, but should be used with caution because they can miss individuals in early stages of infection and underestimate prevalence.

Ramos-Vara JA, Frank CB, Dusold D, Miller MA. Immunohistochemical Expression of Melanocytic Antigen PNL2, Melan A, S100, and PGP 9.5 in Equine Melanocytic Neoplasms. *Vet Pathol.* 2013 In press.

VDL Pathologist Chad Frank worked with Purdue colleagues to test 50 excisional biopsies of equine melanocytic neoplasms from both schools' diagnostic labs using four mono- or polyclonal markers validated in canine tissue. Immunoreactivity was semi-quantitatively evaluated to compare reactivity among different melanocytic markers in the same tumor. Evaluation of immunoreactivity for all four markers based on cell phenotype and location of tumor cells (superficial vs deep) was also done. They found three of the markers—PNL2, PGP 9.5, and S100 protein—were detected in all 50 neoplasms; none expressed the fourth, Melan A. PNL2 was not expressed in 62 non-melanocytic tumors (equine sarcoids, schwannomas, carcinomas, sarcomas, endocrine tumors, sex-cord stromal tumors, germ cell tumors, and leukocytic tumors) or in normal tissues other than epidermis. In summary, they showed antibody PNL2 is a sensitive marker of equine melanocytic neoplasms and is more specific than S100 protein or PGP 9.5. In contrast, the monoclonal antibody to Melan A did not react with any of the equine melanomas. ▲

Photo: Flickr/© "Cow Elk," KitAy. Used under CC BY 2.0.



Get to Know the Laboratory

New Members Join the Lab Team

Greta M Krafsur's circuitous route to veterinary school and pathology began with a bachelor's degree in textile science and a master's degree in nonwovens engineering and polymer science. Realizing the happiest days of her life were spent working on her family's four-generation farm in South Dakota, Greta's passion for Angus cattle inspired her to seek out CSU's VDL research lab and a mentor that will allow her to study bovine respiratory disease and develop expertise in the pathogenesis of respiratory disease in feedlot and cow/calf operations. In her spare time, Greta attends her sons' sports events.



Julie Wright came to work at the Veterinary Diagnostic Lab in June as an administrative assistant and transcriptionist. Julie was raised in Fort Collins and has recently returned to the area after living out of state for the past 19 years. She brings a wealth of knowledge with her working as a medical transcriptionist, working for various hospitals and clinics for the past 26 years. She enjoys spending time with her family, camping and biking, and is very happy to be back in Fort Collins again.



Paula Schaffer received her DVM from the University of Tennessee, Knoxville, and then pursued an internship in small animal medicine, surgery, and emergency prior to completing CSU's anatomic pathology residency. In her spare time she enjoys spending time with her horse and riding in the foothills of Fort Collins.



Michele Miller is the receptionist and official greeter at the Diagnostic Medicine Center. A CSU graduate who grew up in Golden, Michele is an artist, skier and mom of two teenage boys.




Jennifer Malmberg spent much of her life in rural Nebraska, but was born in Glenwood Springs. With a long-standing career goal to help conserve biodiversity, she first became interested in pathology when, working as a Nebraska field biologist to monitor a bighorn sheep repopulation, she witnessed a large-scale outbreak of pneumonia. After graduating from CSU with a DVM in May 2013, she began the combined residency in anatomic pathology and PhD program. She looks forward to pursuing her interests in diseases at the wildlife/livestock interface, host diversity and the pathogenesis and transmission of infectious diseases with global public health implications. Outside work, she enjoys running, traveling and backpacking with her husband and three dogs.



Cindy Arieta is a Colorado native who grew up in the farming and ranching communities in the southern part of the state. She has always worked in the medical field and spent many years at Parkview Medical Center in Pueblo in the laboratory and pathology departments. She is excited about the opportunity to work at the CSU Veterinary Diagnostic laboratory. She enjoys yoga, hiking and reading.

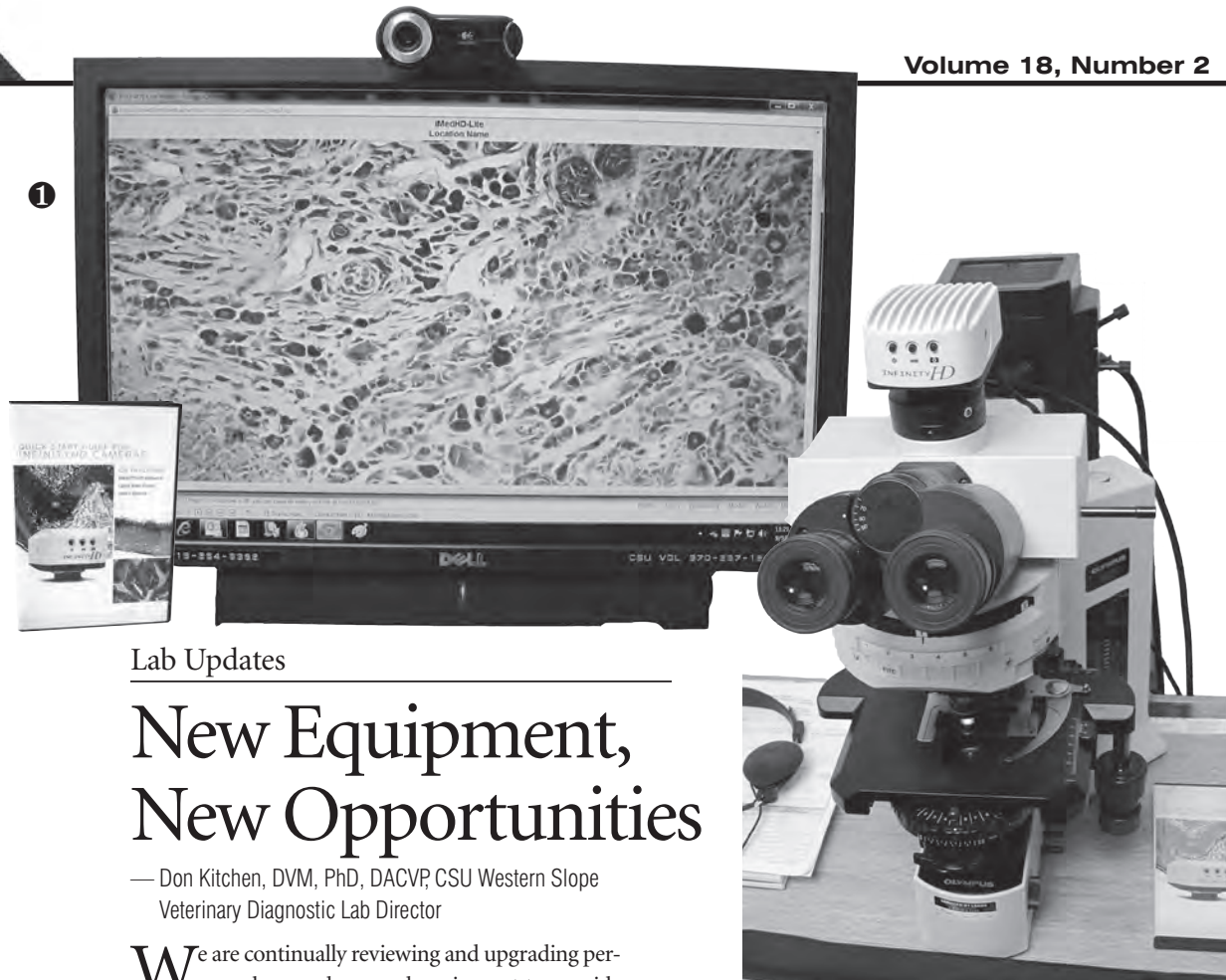

Janice Inman joined the VDL in April as finance and project manager. She has been with CSU since May 2006, spending five years in Business and Financial Services and two years in Clinical Sciences. She is excited about continuing to work in CVMBS within the VDL and the great works done here. Before coming to CSU she had years of accounting experience in industry and public accounting firms. Raised in Loveland and a graduate of University of Nebraska at Kearney, she enjoys being outdoors — a good thing with five dogs. She is a creative spirit who enjoys dancing, being active, and socializing. ▲



CSU Veterinary Diagnostic Lab residents were very successful in passing American College of Veterinary Pathologist board certification exams in 2013. Our congratulations go out to:

- Paula Schaffer
- Alana Pavuk
- Julia Ryseff
- Laura Brandt
- Shannon McClelland



Lab Updates

New Equipment, New Opportunities

— Don Kitchen, DVM, PhD, DACVP, CSU Western Slope
Veterinary Diagnostic Lab Director

We are continually reviewing and upgrading personnel, procedures and equipment to provide up-to-date, cutting-edge diagnostics for Colorado's Western Slope. These new capabilities will allow us to be more efficient and timely and provide the best services possible to our clientele. The CSU Western Slope Diagnostic Laboratory has recently installed several innovative equipment upgrades that

will be able to provide some important tests and procedures here on the western slope that we have previously sent to the main laboratory in Fort Collins.

- 1. TELEPATHOLOGY UNIT.** Affectionately called iMed by the faculty, it allows us to virtually consult directly with pathologists at the main laboratory in real time. Case slides can be shared and reviewed with nearly a dozen board-certified pathologists in Fort Collins, allowing same-day review of difficult or problematic cases. The image clarity is amazing and very diagnostic, and it capitalizes on an efficient method of review used extensively in human medicine.
- 2. MOLECULAR DIAGNOSTICS.** Our remodel and installation is now complete, allowing us to have a separate and isolated area dedicated to molecular diagnostics. We have been doing "small batch" PCR diagnostics for Trichomoniasis using the 7500 Fast Real-Time PCR System from Applied Bio-Systems since last summer.
- 3. AUTOMATED PCR PROCESSING.** Our new KingFisher-flex 96 Deep Well PCR microprocessor from Thermo Fisher Scientific is a cutting edge real-time PCR technology. The Kingfisher-flex unit is an automated system and provides the capability to process much larger numbers of samples efficiently.





Diagnostic Parasitology

Who's Left? PCR Test Gives Insight

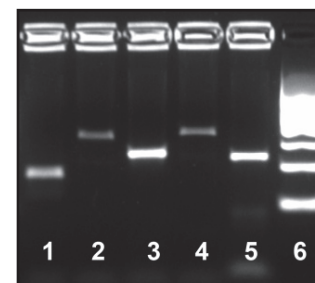
Differentiating ruminant strongyle eggs based on morphology is difficult, so bovine fecal float results are reported simply as strongyle eggs per gram of feces. Specific genera must be documented by larval culture and identification—a process that, although available at CSU VDL, requires specific expertise and two to three weeks to report. This approach has historically been sufficient for managing bovine gastrointestinal strongyle populations; however, with the confirmation of anthelmintic-resistant *Cooperia* and *Haemonchus* populations in U.S. cattle about four years ago, parasitologists no longer consider it sufficient simply to identify strongyle eggs nor take weeks to identify their genera.

With financial support from Merck Animal Health and collaboration with USDA-ARS personnel, CSU's VDL has established a PCR test that differentiates the five major bovine strongyle genera: *Cooperia*, *Haemonchus*, *Ostertagia*, *Trichostrongylus* and *Oesophagostomum*. This test, which has now been available for a little over a year, provides results within just two to three days.

—Lora R. Ballweber, DVM, MS, CSU VDL Parasitology Section Head; and Ashley K. McGrew, PhD, Post-doctoral Fellow

Information gathered from the 251 separate tests performed to date indicate:

- All five genera are still present in many cattle herds.
- *Cooperia* and *Haemonchus* continue to be the primary culprits left behind after treatment.
- Because *Cooperia* is the dose-limiting parasite for most anthelmintics, the fact it remains after treatment is little surprise. The routine identification of *Haemonchus*, however, is a surprise. Although it is the major pathogenic strongyle parasite of small ruminants, *Haemonchus* has not routinely been considered a problem in U.S. cattle.
- While *O. ostertagi*—the most economically important cattle nematode in the world's temperate regions of the world—is still present and common in cattle, *Haemonchus* may be more widespread than previously thought. It will likely become an issue in operations where anthelmintic resistance occurs. ▲



- 1 *Cooperia*
- 2 *Ostertagia*
- 3 *Trichostrongylus*
- 4 *Oesophagostomum*
- 5 *Haemonchus*
- 6 DNA ladder

New PCR makes determining strongyle genera left behind after treatment relatively simple. For instructions on timing, collection and submission of samples, contact the Parasitology Section at (970) 297-1233.

CSU VDL ON THE ROAD: UPCOMING CONFERENCES, SYMPOSIA AND APPEARANCES

VDL Western Slope Lab Director **Don Kitchen**, Rocky Ford Lab Director **Gene Niles**, VDL Director **Barb Powers**, Pathologists **Tawfik Aboellail** and **Gary Mason**, Avian Diagnostics and BSL3 Operations Section Head **Kristy Pabilonia**, Chemistry and Toxicology Section Head **Dwayne Hamar**, Bacteriology Section Head **Doreene Hyatt** and Virology Section Head **Hana Van Campen** represented VDL at the annual meeting of the **American Association of Veterinary Laboratory Diagnosticians**, Oct. 17-23, in San Diego. **Aboellail** presented his investigative pathology study on pathologic lesions and pathogenesis of percutaneous infection of CD-1 mice with western equine encephalitis virus. **Hamar** presented his work on sampling for selenium toxicity. **Pabilonia** presented on *Salmonella* in backyard poultry.

Pabilonia attended a conference on influenza control options in **Cape Town, South Africa**, in September, an **AVMA Future Leaders Meeting** at the association's Illinois headquarters in September, and an **AAVLD accreditation site visit** in November. She and VDL Pathologist **Colleen Duncan** will travel to Honolulu Nov. 18 through 22 for research on **Hawaiian Monk Seals**.

VDL Pathologist **EJ Ehrhart** was at the first **Comparative Ocular Pathology Society meeting** in September in Madison, Wis. Look for him also at the annual meeting of the **American College of Veterinary Pathologists**, Nov. 16 through 20 in Montreal.

Powers, Hamar, Pabilonia, Van Campen, Pathologist **Patricia Cole** and VDL Lab Coordinator **Charlie Davis** were in attendance at this year's **Colorado Veterinary Medical Association** annual meeting in Loveland in September, where **Cole** was named this year's outstanding faculty member (see page 1).

Look for **Powers** and **Davis** at this year's **National Western Stock Show** in Denver and the **Colorado Cattlemen's Association mid winter meeting**, both in January.

VDL Pathologist **Sushan Han** was in **Nicaragua** in September as part of a three-year project to help develop veterinary diagnostic lab capacity and ultimately improve livestock production in that country. She returns to Nicaragua in January. In October, she presented a workshop on heart disease in great apes, a case study on endocarditis in a golden-cheeked gibbon, and a seminar covering the lab's recent retrospective study on metastatic mineralization in 18 captive two-toed sloths at the **American Association of Zoo Veterinarians Annual Convention** in Salt Lake City in October. She also attended a meeting of the **Washington Department of Fish and Wildlife** in Chehalis in October to present the pathologic findings to date on a rare hoof disease of free-ranging Roosevelt elk from the region. This spring, she travels to Nairobi on an assignment to develop research and teaching collaborations with **University of Nairobi**.



REGULAR COLUMNS

- **ZOO CORNER** p. 3
Endocarditis in a gibbon.
- **PUBLIC HEALTH** p. 5
Salmonella in fair poultry.
- **CASE STUDY** p. 7
Oral canine mast cell tumor.
- **DISEASE UPDATES** p. 8
Non-neoplastic skin lesions.
- **LAB UPDATE** p. 13
Meet new staff members.


LAB LINES

INSIDE THIS ISSUE

LAB NEWS p. 1
VDL pathologist named CVMA outstanding faculty.



OUTREACH p. 6
Got a question beyond diagnostic results? We can put you in touch with answers.



PRODUCTION MEDICINE . . . p. 9
Sample submission recommendations for bovine trichomoniasis now updated.

VDL IN PRESS p. 10
A roundup of recent work by VDL faculty members.



LAB UPDATES p. 14
New equipment additions offer new diagnostic opportunities for clients.



PARASITOLOGY p. 15
VDL's revolutionary PCR can help diagnose anthelmintic failures in rapid time.

Update from the Director

Last year, the Fort Collins region survived fires. This year, in September, we again survived a natural disaster of floods. Many of the laboratory staff were cut off from the laboratory for a few days and packages could not be delivered to us. Many in the region suffered severe losses of property and some even lost their lives.

We have recovered from this flood in an excellent manner, and the state had really outstanding emergency response, which included air evacuation of people and over 600 dogs and cats from flood-ravaged areas. Shortly after the floods, we were at the Colorado Veterinarian Medical Association Annual Convention, where our very own Dr. Patricia Cole received the Outstanding Faculty of the Year Award. Our congratulations also go out to our State Veterinarian, Dr. Keith Roehr, who received the Veterinarian of the Year Award. In July, we welcomed our new pathology residents to the laboratory and we had new staff replace those that have retired or moved.

We hope you enjoy the articles in this issue of LabLines. Note our new "Zoo Corner" and our contin-



**BARBARA POWERS,
DVM, PHD, DACVP
DIRECTOR**

ually overflowing Research Activities area. Also note informative articles in parasitology, poultry and salmonellosis, bacteriology, equine skin disease, and atypical mast cell tumor presentations.

Our Case Coordinator, Charlie Davis, has multiple pieces on how to get the best information and assistance from us. Also see the improvements in technology at the Western Slope Diagnostic Laboratory, all aimed to better serve you. We ended the fiscal year with an increase in accessions in many areas. I hope this increase is a reflection of the qual-

ity, timely service our lab provides.

We look forward in January to meeting with our External Advisory Committee, and we welcome any comments to them or to us regarding our services. We always strive to provide you with the best service possible.

Best wishes,

Barbara E. Powers