

## LAB LINES

Diagnostic news and trends from the Colorado State University Veterinary Diagnostic Laboratories  
Volume 16, Number 2  
Fall/Winter 2011

### Lab Updates

## AAVLD Grants Highest Honors to Powers

Veterinary Diagnostic Lab Director Barb Powers received the 2011 E.P. Pope Award from the American Association of Veterinary Laboratory Diagnosticians in October, the national association's highest honor.

Powers has dedicated her entire academic career to Colorado State University, starting as an assistant professor and eventually becoming a full professor and, in 1998, VDL director. She has served on nearly 50 graduate committees and has dedicated herself to advancing the field of veterinary pathology through teaching, research and outreach.

"Dr. Powers has been tirelessly devoted to making our diagnostic laboratory one of the best in the nation, as well as providing excellent service to DLAB clients, and being a mentor to our students while maintaining her own research interests," said Lance Perryman, dean of the College of Veterinary Medicine and Biomedical Sciences. "This award is a reflection of her dedication not only to her profession, but to her students and colleagues."

Powers earned her bachelor's, DVM and master's degrees from Purdue and her doctorate at Colorado State. A diplomate of the American College of Veterinary Pathologists in anatomic pathology, her research interests and areas of specialty include surgical pathology, oncology, radiation pathology, orthopedic pathology and equine endometrial pathology.

At the AAVLD, Dr. Powers served as president in 2006, on the executive board from 2001 to 2006, on the accreditation committee for 12 years, and co-chairs the AAVLD/USAHA committee on the National Animal Health Laboratory Network.

Dr. Powers' past honors include the SmithKline Beecham Research Award in 1993; the Colorado Veterinary Medical Association's award for CVMBS Outstanding Faculty of the Year in 2002; and CVMA Veterinarian of Year Award in 2005. She was recognized for best manuscript in the Journal of Veterinary Diagnostic Investigation in 2004; served on the Board of Directors and



CSU Veterinary Diagnostic Lab Director Barb Powers accepts the AAVLD's highest honor from President Gary Anderson, at the group's annual meeting in October.

was President of CVMA; has had more than 200 abstract presentations; published 183 refereed papers; and been a guest speaker across the United States and abroad. ▲

**Presented in memory of Edward P. Pope, one of the founders of the American Association of Veterinary Laboratory Diagnosticians and the association's distinguished secretary/treasurer from 1959 to 1972, the E.P. Pope award has been given annually since 1974. The highest award given by the nation's professional association for veterinary diagnosticians, it is presented to an individual who has made noteworthy and significant contributions to the association in regard to implementing and advancing the recognition of the specialty of veterinary diagnostic laboratory medicine.**

## Food Animal Production Medicine

# Systematic Approach to Diagnosing Small Ruminant Abortions

Winter brings with it the impending lambing and kidding season, and, unfortunately, the first abortions. At the Veterinary Diagnostic Laboratory, we receive many cases of second and third trimester abortions and stillbirths from sheep and goats, representing large range flocks as well as increasing numbers of small, intensively managed hobby flocks. Loss of lambs and kids in either situation can be devastating to producers. Abortion diagnosis focuses on identifying infectious causes of abortion, which is essential for preventing contamination of the facilities and halting spread to susceptible herd mates, with the goal of curtailing abortion storms while minimizing zoonotic risk. A systematic approach to approaching abortion diagnosis and sample collection can help achieve that goal.

## HISTORY COLLECTION

The start of any abortion case should involve a thorough history and accurate determination of the abortion rate within the herd. Abortion in any given herd is generally less than 2 percent; abortions involving more than 5 percent of the herd and clusters of abortions occurring within two weeks' time may indicate a more serious problem. Important historical information includes:

- History of previous abortions in both dam and herd
- Size of the flock
- Range of ages of aborting females
- Stage of gestation at fetal loss
- Animal movement on the farm, including all recent additions of animals
- Recent handling, such as immunization and shearing
- Feed sources and recent nutritional changes
- Vaccination history
- Environmental factors, including exposure to toxic plants and chemicals, temperature extremes or stress
- Exposure to other species.<sup>1,2</sup>

## SAMPLE COLLECTION

**Dam physical exam.** Though, unfortunately, it's often excluded, a complete physical exam of the aborting ewe or doe should be conducted. Evaluate for current illness, including fever, general physical condition and nature of vaginal discharge, to help differentiate infec-

— *Sushan Han DVM, PhD, DACVP, CSU VDL Pathologist and CSU Microbiology, Immunology and Pathology Assistant Professor*

tious abortion from metabolic or other non-infectious abortions.

**Acute and convalescent sera.** In many cases, fetal and placental lesions may be absent, yet maternal titers may reflect current bacteremia or viremia and may help to diagnose infectious abortion. Acute (at the time of abortion) and convalescent (three weeks post-abortion) serum titers to common

abortifacients are currently offered in a comprehensive panel at the lab. (See chart on page 3.)

**Placenta.** The placenta is the critical link between the maternal and fetal components of abortion. Many abortifacients will only have organisms and lesions within the placenta, with fetal death simply a result of placental failure and hypoxia. Collection and examination of the entire or even partial placenta is important regardless of environmental contamination or autolysis. Many infectious organisms can be cultured or identified by PCR, and histological lesions persist despite autolysis. Gross examination can also help identify infectious and non-infectious causes of placental failure. Submission of the placenta fresh on ice is preferable. If the placenta is no longer available, culture and submission of a swab from the dam's uterus within three days of abortion can substitute. Specimens are essential for bacterial culture and PCR of infectious organisms.<sup>2</sup>

**Fetus.** Gross and histological examination of the aborted fetus is essential for diagnosis of infectious abortion and to identify congenital lesions. Few infectious organisms have subtle gross lesions, and the majority of aborted fetuses are variably autolyzed and otherwise grossly normal. Submission of the entire fresh fetus on ice is preferable, and necropsy will be performed at the VDL.

*‘Though, unfortunately, it’s often excluded, a complete physical exam of the aborting ewe or doe should be conducted.’*

Continued on page 4

The CSU VDL small ruminant abortion screen covers the four most common abortifacients, plus border disease virus and aerobic bacteria. The screen is intended to be an all-inclusive tool for detecting infectious abortion, though individual tests can be tailored to the needs of each farm based on herd history, risk factors and previous

diagnostics. In deciding which samples to submit, pay careful attention to each of the three components of abortion: dam, placenta and fetus. Submission of more than one abortus is often very helpful, as multiple etiologies may be involved and individual variation in lesions and cultures may not be representative of the herd problem.

| PANEL PRICE                | LAB                          | AGENT  | TEST              | SAMPLE  | INDIVIDUAL TEST COST          |
|----------------------------|------------------------------|--|-------------------|---|-------------------------------|
| <b>\$80</b>                | Bacteriology                 | Brucella ovis<br>Brucella melitensis<br>Campylobacter sp.<br>Misc. Aerobes | Aerobic Culture ^ | Fetal lung<br>Fetal Liver<br>Abomasal contents<br>Placenta**                            | \$18                          |
|                            | Molecular Diagnostics        | Chlamydomphila abortus   | PCR*              | Fetal lung<br>Fetal liver<br>Placenta**   | \$35                          |
|                            |                              | Coxiella burnettii   | PCR*              | Fetal lung<br>Placenta**  | \$60                          |
|                            |                              | Toxoplasma gondii  | PCR*              | Fetal brain<br>Fetal heart<br>Placenta (Cotyledon only)                                 | \$35                          |
|                            | Parasitology                 | Toxoplasma gondii  | MAT               | Fetal peritoneal fluid  | \$20                          |
|                            | Virology                     | Border Disease Virus   | IFA               | Fetal lung<br>Fetal liver<br>Fetal kidney<br>Fetal spleen<br>Fetal thymus<br>Placenta** | \$5                           |
|                            | Histopathology (Four slides) |  |                   | Fetal tissues   | \$39                          |
| <b>Comprehensive Panel</b> |                              |  |                   |   |                               |
|                            | Serology                     | Chlamydomphila abortus   | ELISA             | Acute and convalescent serum  | \$20 paired / \$15 indiv.     |
|                            |                              | Coxiella burnettii (phase I/II)  | IFA and Titer     | Acute and convalescent serum  | \$35 paired / \$24 indiv.     |
|                            |                              | Brucella sp.   | ELISA             | Acute only  | \$10                          |
|                            |                              | Toxoplasma gondii  | MAT               | Acute only  | \$20                          |
|                            |                              | Campylobacter sp. (sheep)  | LAgglutination    | Acute and convalescent serum  | \$9.20 paired / \$5.60 indiv. |
|                            | Chem/Toxicology              | Copper analysis  | Flame AAS         | Fetal liver   | \$12                          |
| <b>Additional Tests</b>    |                              |  |                   |   |                               |
|                            | Virology                     | Blue Tongue Virus  | PCR*              | Fetal lung<br>Fetal brain   | \$30                          |
|                            |                              |  | Serology          | Fetal peritoneal fluid  | \$7                           |
|                            | Histopathology               |  | Each add'l slide  |   | \$10                          |
|                            | Parasitology                 | Neospora caninum   | PCR               | Fetal brain<br>Fetal heart<br>Placenta (cotyledon)                                      | \$35                          |
|                            |                              | Neospora caninum   | ELISA             | Fetal peritoneal fluid  | \$10                          |
|                            | Chemistry / Toxicology       | Nitrate  | Nitrate Analysis  | Fetal eye   | \$10                          |

^ Tissues will not be pooled unless otherwise indicated.

\* Tissues will be pooled unless otherwise indicated.

\*\* Unless indicated, include cotyledon and intercotyledonary space.

**FOR MORE INFORMATION**

Go to [www.dlab.colostate.edu/security2/test\\_info/661.cfm](http://www.dlab.colostate.edu/security2/test_info/661.cfm) for more details of the small ruminant abortion screen

**Fresh and formalin fixed fetal tissues.** Veterinarians can perform necropsy on the farm and submit tissues, either fresh and formalin-fixed, for laboratory testing and histopathology. Critical fresh tissues to collect are outlined on the abortion screen under each individual test, and include fetal aboma-

sal fluid, which is essentially amniotic fluid, and fetal thoracic or peritoneal fluid, which is used for fetal serology. Histopathology should include a representative section of all major viscera, including the brain, heart and diaphragm. ▲

## COMMON CAUSES OF ABORTION IN EWES AND DOES

### *Chlamydophila abortus*

- Common cause of small ruminant abortion in western North America.
- Shed in vaginal secretions, afterbirth, semen and feces.
- Perpetuated in a herd by subclinically infected individuals via oral-nasal and venereal transmission, and by avian reservoirs.
- Environmental contamination is a serious problem where animals are exposed to soiled bedding and feed.
- Causes early fetal reabsorption and common late term abortion with still- and weak-born lambs and kids.
- Aborting females are moderately sick and continue to shed organism for up to three months after abortion.
- Affected animals develop short term immunity lasting about three years, with recurrence of abortion in mature animals following waning immunity. Naïve animals are particularly sensitive, with high rates of abortion and illness
- Important zoonotic risk to handlers, particularly pregnant women.

### *Coxiella burnetii*

- Shed chronically in feces and semen; particularly high numbers shed vaginally and in afterbirth at parturition or abortion and for several weeks to months afterwards.
- Subclinical dams shed again at subsequent births, leading to significant environmental contamination.
- Spread by oral-nasal contamination
- Causes early embryonic reabsorption and common late term abortion and stillbirth; most commonly in naïve dams.
- Particularly important pathogen in goats.
- Important zoonotic pathogen, with particular risk for immunosuppressed people and pregnant women.

### *Campylobacter fetus fetus* (sheep) and *C. jejuni jejuni* (sheep and goats)

- Particularly hardy in the environment; efficient bedding

and feed contamination, with additional dispersal by birds and animals.

- Shed in and vaginal secretions and feces of clinically and subclinically infected sheep and goats.
- Common cause of sporadic late term abortion in sheep and especially naïve ewes, resulting in abortion rates of 5 percent to 35 percent.
- Immunity post-abortion is long term, though bacterial contamination is perpetuated within the herd, affecting new introductions in subsequent years.
- Affected ewes can present with limited diarrhea and recover without incident; many aborting ewes completely non-clinical.
- An important enteric zoonosis for people.

### *Toxoplasma gondii*

- Protozoan spread by feline reservoirs via fecal contamination of bedding and feed.
- Common cause of early embryonic reabsorption, late term abortion, mummification, stillbirth and weak-born young in naïve sheep and goats.
- Can affect from 5 percent to 100 percent of the herd.
- Dam is generally unaffected and develops long term immunity.
- Sheep and goats are dead-end hosts for this pathogen, but environmental exposure can be a zoonotic risk for people and animals, especially pregnant women.

### Other less common causes

- *Listeria* sp., *E. coli*, *Brucella* sp., *Salmonella* sp., *Mycoplasma* sp., *Leptospira* sp.
- Blue tongue virus, border disease virus, Cache Valley fever.
- *Neospora caninum*.
- Dietary deficiencies of copper, selenium or iodine.
- Environmental stress, trauma or dam metabolic disease.

## SOURCES

1. Mearns, R. Abortion in sheep. 1. Investigation and principal causes, 2. Other common and exotic causes. *In Practice*. 2007;29(1):40-46,83-90.
2. Menzies PI. Control of important causes of infectious abortion in sheep and goats. *Vet Clin North Am Food Anim Pract*. 2011 Mar;27(1):81-93.

## E-services and Other Technology

# Clear Your Truck: CSU VDL Now Supports Electronic Certificates

For computer-savvy veterinarians, electronic veterinary certificates can be important time and space savers. Computerized electronic systems offer a handy, portable way to store business information, such as client and market information, while eliminating lost papers and copies.

Plus, electronic certificates can be *fast!* The certificates and test results are available on-line as soon as the laboratory technicians enter the results. No more “lost-in-the-mail.”

Two electronic veterinary certificates systems are available to choose from, and CSU VDL's Fort Collins and Rocky Ford laboratories have been a part of both electronic reporting systems since 2008: USDA's Veterinary Services Process Streamlining, and GlobalVetLink. Here's how to get started:

- To get started in the USDA VSPS, apply for e-authentication at <https://vsps.aphis.usda.gov/vsps/>
- To contact GlobalVetLink, new customers can call (515) 296-0860, email [Info@GlobalVetLink.com](mailto:Info@GlobalVetLink.com), or visit [www.globalvetlink.com](http://www.globalvetlink.com). GlobalVetLink will help you learn its system.

CSU VDL offers clients electronic Coggins (eEIA) reporting, which Global VetLink reports is the most widely used electronic certificate in its system. Electronic reporting of *T. foetus* is also available.

Granted, technology does have its disadvantages. Some practices include areas that are out of “wireless-connection” range, and therefore will have limited access to the Internet-based services. Plus, someone will still have to take the time to enter client information into your electronic data base.

However, once the information is stored, it can be transferred easily onto new electronic forms. Since the owner, animal and test information have already been entered into GlobalVetLink, for instance, it takes only a few clicks of the mouse to create a health certificate approved for travel anywhere in the United States, which can be automatically forwarded to both the state of origin and the state of destination. Electronic certification also opens additional opportunities for value-added clinic business. Although electronic Coggins certificates don't require photos, we have found that being able to offer digital photos of horses are a selling point for clients. ▲

— Hana Van Campen, DVM/PhD/DACVM, CSUVDL Virology Section Head



## COGGINS SEASON TIME-SAVING TIPS

- **Pre-enter owner and animal information, as well as new clients acquired through the year.**
- **Double-check horse ages.** Using the date-of-birth option avoids having to check the age every year.
- **Check your camera's resolution setting.** The smaller the digital photo, the faster the pictures will upload. A 1- or 2- megapixel picture will suffice. “Email quality” is ideal.
- **Use a “field Coggins form” to help speed up data collection in the field.**
- **Use a whiteboard if you're going to be taking several photos in a day.** Write the horse's name on the whiteboard, hold it in the side of the photo frame as you take it, and you have an easy and instant identity of horses in all photos.
- **Give your clients access to their own certificates through the system.** It saves you from having to print for them.

Source: GlobalVetLink

### REGULATORY COMPLIANCE

CSU VDL in the Field: Case Study

# Lead Toxicosis, Public Health Risk?

— Jim Kennedy, DVM, MS, Director, CSU VDL Rocky Ford Branch

A two-month-old crossbred male beef calf was presented for necropsy and diagnostic evaluation. The owner reported the loss of 15 calves from a herd of 80 pairs. The cows were grazing native pasture with no supplementation, and water was provided from the local city system. No vaccinations had been given to the calves at the time of presentation. One month later,

a second calf was submitted, with the owner reporting an additional eight losses and two blind calves. The local county extension agent was contacted to do an on-site visit, to look for the presence of toxic agents including lead and weeds and to offer a general opinion.

The history of blindness led to request lead levels in liver tissues. We found them to be 110 p.p.m. Greater than 10 p.p.m. is considered toxic. No toxic plants were identified, but the pasture was suffering from drought. A large quantity of paint chips was found near a drainage pipe from the adja-

cent city water facility. Those findings prompted us to test a frozen liver sample from the first calf for lead. It was 160 p.p.m. When the paint chips were analyzed, we detected 10 percent lead content, upon which public health officials and environmental agencies were contacted.

### A PUBLIC HEALTH TEAM

Lead is a commonly identified toxin. Some sources of lead include car batteries and lead based paint. Buildings, especially those that underwent construction or repainting prior to the 1970s, frequently were painted with lead-based paint. There is no approved antidote available for lead toxicity, and the length of time lead

remains after ingestion is not well established, with ranges from 45 days to more than 2,700 days.

The CSU Diagnostic Lab system has diagnosed lead toxicity in four cases in 2011, an increase over the number in the previous year. There is no apparent reason for the increased number, but producers should be reminded to make a thorough surveillance of pastures and pens before turning cattle out, rather than looking for a lead source after animals die.

Submission of samples for lead levels should always be considered when CNS signs are present. The failure in this case to diagnose lead toxicity initially was a result of inadequate history. Had lead been suspected on the initial presentation, management decisions could have been made that would have avoided further loss of livestock.

Lead toxicity within food-producing animals raises concerns as to what the disposition of those animals should be, and what should be done to ensure lead tainted food doesn't enter into the food chain. The above case is of special interest due to the number of animals involved, the number lost, and follow-up testing showing levels in some animals that still surpassed toxic levels.

This case demonstrated the need for multiple agencies to communicate and address multifaceted problems and the role the veterinarian plays in our society. Disposition of cattle with lead poisoning as it relates to food safety is another issue of concern. Most often we look at lead toxicity at an individual level; however, this particular case has further ramifications. There is no current requirement for lead levels to be determined prior to slaughter and no acceptable lead level has been determined. However, a 2008 study conducted by FSIS and published in its Redbook is reflected in the table below. The conclusion that can be drawn is that lead is entering our food chain at, albeit, a very low level. But the question arises as to what level it becomes significant. ▲



Lead is a commonly identified toxin and should be suspected in toxicosis of cattle with access to discarded lead-acid batteries, as well as buildings and equipment painted before the use of lead-based paint was halted.

| TISSUE | NUMBER OF SAMPLES | NUMBER POSITIVE | PERCENT POSITIVE | RANGE (PPB)    | MEDIAN (PPB) | MEAN (PPB) | STD. DEV. |
|--------|-------------------|-----------------|------------------|----------------|--------------|------------|-----------|
| Kidney | 319               | 195             | 61.1             | 0.0 to 1237.2  | 30.16        | 46.88      | 112.86    |
| Muscle | 319               | 33              | 10.3             | 0.0 to 1359.28 | 0.0          | 12.59      | 82.82     |

Source: Statistical analysis of lead levels in kidneys and muscles from beef cows, 2008 FSIS exploratory assessments.

## Diagnostic Interpretation

# Assessing Bovine Neurological Disease

— Jim Kennedy, DVM, MS, Director, CSU VDL Rocky Ford Branch, and Hana Van Campen, DVM/PhD/DACVM, CSUVDL Virology Section Head

The veterinary practitioner faces challenges in making timely and accurate diagnoses of disease, and one of the greater challenges is when the animal is demonstrating neurological signs.

In general, neurological disease can be defined as any departure from the normal, but in the case of cattle, that departure is often masked by the animal's response to human interaction, its environment and diseases of other systems. The practitioner may have never seen the animal before, and the observation skills of some owners frequently leave gaps that prevent a reasonable list of differentials to be formulated. Any number of potential diseases might yield neurological signs, including parasitism, nutritional deficiencies/imbbalances, neoplasia, toxins, bacteria, viruses and trauma. Diagnosing neurological disease is further complicated by the fact that animals with excessive fevers, acute blood loss, and compromised respiratory systems with hypoxia may exhibit neurological signs, as well.

## WHERE TO BEGIN

A key to diagnosing any disease is a good history. The history coupled with the clinical signs permits the veterinarian to formulate an initial differential diagnosis. It is essential that this history addresses the rest of the herd and include such things as feed and water sources, onset of clinical signs, number of animals showing signs, number of animals exposed, breed, and vaccination and treatment history.

One final fair warning: Always leave rabies on the differential list. Several years ago I made a farm visit treat a down cow. After nearly five days of treatment the cow died, and I was called to perform a necropsy on the animal. Finding no signs to explain the condition, I loaded my equipment, told the owner it was probably nutritional and began to drive away. Only as I pulled out of the driveway did rabies come to mind. I went back, removed the brain, and the laboratory confirmed a diagnosis of rabies. The rabies vaccinations that followed for both owner and me, who had extensively exposed ourselves, taught me a valuable lesson. ▲

| ETIOLOGY   | DIAGNOSTIC INFORMATION  | DIAGNOSTIC TESTS   |
|--|---|--|
| <b>Trauma</b>  |   |  |
| Dystocia, buller injury, electrocution, chute injury | History   | Necropsy, gross lesions  |
| <b>Toxins</b>  |   |  |
| Lead   | Whole blood, urine, stomach contents, liver, kidney, refrigerated       | Toxicology, lead   |
| Organophosphate                                      | Whole blood, refrigerated<br>Brain, frozen immediately, ship on dry ice | Toxicology, acetylcholinesterase   |
| Nitrates   | Feed and water analysis   | Toxicology, Nitrates   |
| Cyanide  | Feed analysis   | Toxicology, Cyanide  |
| <b>Nutritional</b>                                   |   |  |
| Polioencephalomalacia                                | Sulphates in water, Distiller grains, Thiaminase                        | Toxicology<br>Histopathology   |
| Acute grain overload                                 | History   | Rumen pH   |
| <b>Viruses</b>                                       |   |  |
| Rabies   | Fresh, cross-section of brain stem and cerebellum                       | Rabies, Direct fluorescent antibody  |
| Bovine viral diarrhea, in utero infection            | History of exposure to PI cattle  | Necropsy, cerebellar hypoplasia, hydrocephalus, microphthalmia, BVDV IHC stain |
| Bovine herpesvirus-5                                 | Fresh brain   | BHV-5 PCR  |
| Bovine leukosis virus, intravertebral tumor          | Necropsy  | Histopath, BLV PCR   |
| Bluetongue virus                                     | Blood   | Serology   |
| <b>Bacteria</b>                                      |   |  |
| Abscess, cerebral, vertebral                         | Necropsy  | Gross lesions, Bacterial culture   |
| Otitis media, extension into cerebrum                | Necropsy  | Gross lesions, Bacterial culture   |
| Listeria monocytogenes, microabscesses, brain        | Necropsy  | Bacterial culture  |
| Tetanus, Clostridium tetani                          | Vaccination history, clinical signs                                     |  |
| Clostridium perfringens                              | Clinical signs, feces   | Bacterial culture, PCR, toxin ELISA  |
| Botulism, Cl. botulinum                              | Feed history and appearance, clinical signs                             |  |
| <b>Parasitic</b>                                     |   |  |
| Nervous coccidiosis, Eimeria zurnii                  | Age, bloody diarrhea  | Fecal exam   |
| <b>Metabolic</b>                                     |   |  |
| Hypocalcemia, Milk fever                             | History recent calving  | Blood chemistry analysis   |
| Hypomagnesemia, Grass tetany                         | History of new grass  | Blood chemistry analysis   |
| Hypokalemia  | History, grazing winter wheat   | Blood chemistry analysis   |
| Ketosis  | Early lactation   | Ketones in milk or urine   |
| <b>Genetic</b>                                       |   |  |
| Alpha-mannosidosis                                   | Angus cattle  | Breed registry   |
| Beta-mannosidosis                                    | Saler cattle  | Breed registry   |
| Protoporphyrin                                       | Limousin cattle   | Breed registry   |
| Spastic syndrome                                     | Holstein, Guernsey, Hereford  | Breed registry   |
| Spastic (heel) paresis                               | Maine-Anjou, Belgian Blue, Shorthorn, Friesian, Brahman                 | Breed registry   |
| <b>Other</b>   |   |  |
| Myasthenia gravis-like syndrome                      | Response to edrophonium   |  |
| Hypoxia  | Secondary to respiratory infection<br>Secondary to acute blood loss     | Clinical signs<br>Hematocrit, total protein                                    |
| BSE  | Obex  | ELISA, IHC   |

## Diagnostic Quality Assurance

# How to Interpret and Report Gastrointestinal Biopsies

Colorado State University Veterinary Diagnostic Lab is well positioned to help reach the consensus sought worldwide, led by the American College of Veterinary Internal Medicine (ACVIM), on how to interpret and report gastrointestinal biopsies.<sup>1</sup> The number of biopsies VDL receives annually prompted our anatomic pathologists and hospital clinicians to standardize pathologic interpretations and set the clinical criteria for inclusion of gastrointestinal disorders as cases of inflammatory bowel disease (IBD). In doing so, we establish histopathologic guidelines for evaluating gastrointestinal (GIT) biopsies and enhance consistency of inter-pathologist interpretation and identification of GIT lesions. CSU VDL uses the criteria established by the ACVIM consensus group.

— *Tawfik Aboellail, BVSc, MVSc, PhD, DACVP, CSU VDL Pathologist*

■ **Fast preservation:** Autolysis usually hampers accurate evaluation of subtle lesions.

Six adequate or marginal (only villous tips and superficial lamina propria) biopsies are needed to reach a conclusive disease in cats. The number of specimens needed in dogs increases to six or seven adequate or ten to 15 marginal biopsies to diagnose villous atrophy and lymphangiectasia in mild to moderate inflammation. Crypt lesions require 13 adequate or 28 marginal biopsies to be clearly identified. Inadequate biopsies (only villous tips) are not sufficient to rule in or out pathologic IBD diagnosis.

## CLINICAL DIAGNOSIS

Clinical diagnosis of IBD requires a spectrum of gastrointestinal disorders associated with idiopathic inflammation of stomach, intestine, colon or any combination of these, characterized by the following:

- **Chronicity:** Gastrointestinal signs lasting for more than three weeks
- **Histopathologic evidence of mucosal inflammation**
- **Inability to document a particular cause of GIT inflammation**
- **Inadequate response to conventional treatment**
- **Clinical response to anti-inflammatory or immunosuppressive drugs**

## GENETIC PREDISPOSITION:

Although genetic predisposition is proven in humans suffering from Crohn's disease or ulcerative colitis, parallel compelling evidence has not yet been proven in small animals. However, certain breeds are more predisposed; Shar Pei, Basenji, German shepherd, Boxer, Rottweiler and soft coated Wheaten terrier dogs seem to be at increased risk. In cats, only Siamese are at increased risk.

## CRITERIA OF A GOOD SPECIMEN

- **Sufficient, both in numbers and quality:** including all layers of mucosa and superficial submucosa
- **Representative:** different areas of inflamed segment or segments in small and large intestines and stomach
- **Good tissue quality:** not pinched or crushed so as to avoid crushing artifacts
- **Correct orientation:** technicians trim and embed GIT biopsies trained

## WHAT TO SEND

It largely depends on whether the pet has evidence of vomiting, small intestinal diarrhea, large intestinal diarrhea, or both. Most veterinarians send stomach, duodenum and colon to represent small and large intestines. Studies, however, show ileum should be included in small intestine specimens if the dog shows enteropathy.<sup>2</sup> This requirement may complicate pre-endoscopic preparation of cleansing solutions and enemas, increasing hospitalization, procedural times and, of course, cost.

## WHAT YOU RECEIVE

VDL pathologists use a standardized form adapted from the consensus group which will accompany your descriptive report. The form documents the number of samples, their quality and morphological changes in the tissue, and it quantitates the inflammatory infiltrate and type.

## DIAGNOSTIC CHALLENGES:

Distinguishing lymphoplasmacytic inflammation from alimentary lymphomas is a major issue that usually confronts pathologists, especially in feline medicine. Lymphomas tend to have monotonous lymphocytic population with clear evidence of epitheliotropism. Some experts say the junction between crypt basal lamina and adjacent lamina propria is usually obliterated.

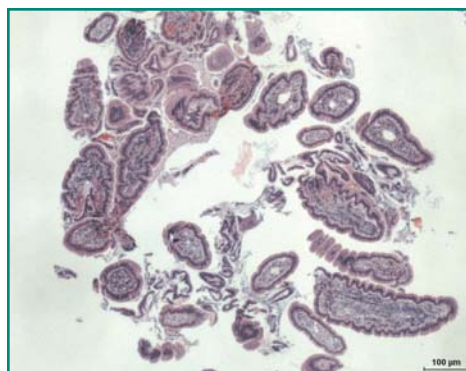
Alimentary lymphoma is now the most common presentation of feline lymphomas, which may present itself in two distinct histopathologic variants:

- **Small-cell lymphocytic villous lymphoma,** a T-cell lymphoma mostly seen at the base of the villi of older cats
- **Large-cell lymphoblastic lymphoma,** which is seen

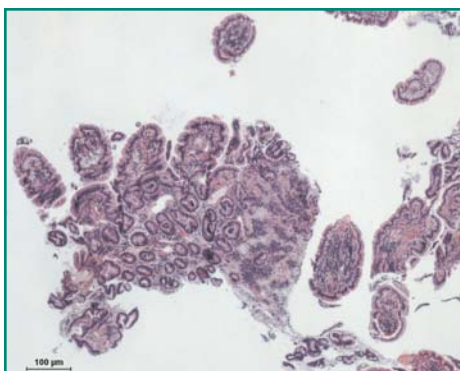
## SOURCES

1. Washabau RJ, Day MJ, Willard MD, Hall EJ, Jergens AE, Mansell J, Minami T, Bilzer TW; WSAVA International Gastrointestinal Standardization Group. Endoscopic, biopsy, and histopathologic guidelines for the evaluation of gastrointestinal inflammation in companion animals. *J Vet Intern Med.* 2010 Jan-Feb;24(1):10-26.
2. Casamian-Sorrosal D, Willard MD, Murray JK, Hall EJ, Taylor SS, Day MJ. Comparison of histopathologic findings in biopsies from the duodenum and ileum of dogs with enteropathy. *J Vet Intern Med.* 2010 Jan-Feb;24(1):80-3.

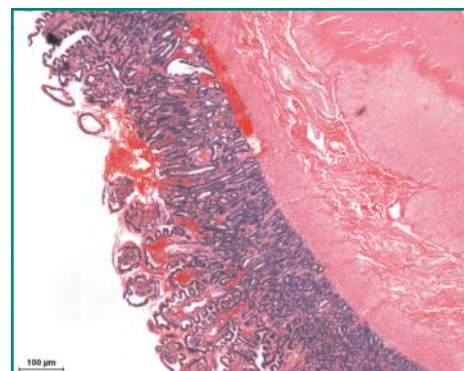




INADEQUATE



MARGINAL



ADEQUATE

at any age and usually carries greater potential for systemic involvement.

If routine histopathology is insufficient to differentiate small-cell villous lymphoma from chronic inflammation, immunohistochemistry might emerge as the key to simplify such differentiation. Immunophenotyping for expression of CD3 and CD79a will give a clear impression of the lineage of the infiltrating lymphocytes and hence correct diagnosis.

Another challenge we face in interpreting chronic gastritis is when we find helicobacter-like bacteria on the surface of inflamed mucosa from pets with chronic

vomiting. The ACVIM group and VDL pathologists have concluded it's almost impossible to differentiate IBD-associated gastritis from helicobacter-associated gastritis by histologic examination. Helicobacter-associated gastritis varies in its severity and is characterized by lymphoplasmacytic gastritis with lymphoid follicular hyperplasia and discernible helicobacter organisms colonizing gastric glands visualized by (Warthin-Starry stain) or proven by PCR or *in situ* hybridization. However, helicobacter organisms are highly prevalent in healthy and sick dogs and cats and a direct causal relationship has not yet been firmly established. ▲

### Advances in Wildlife Diagnostics

## Hoof Deformities in Free-Ranging Elk

Free-ranging Roosevelt elk (*Cervus elaphus roosevelti*) and Roosevelt-Rocky Mountain (*Cervus elaphus nelsoni*) hybrid elk in southwestern Washington were recently reported with severely overgrown and deformed claws. Reports of elk with deformed hooves have occurred sporadically for over a decade, but the number and distribution of these reports increased significantly in 2008.

In spring 2009, we determined the geographical distribution of affected elk herds, characterized hoof lesions, and examined etiologies causing claw deformities, with the goal of establishing a health baseline within a defined study area. We visually evaluated herds and surveyed landowners and hunters, to estimate the prevalence and distribution of affected elk within 15 counties and 11 game-management units in the Cowlitz River Basin.

About 55 percent of all herds in the study area had 30 percent to 90 percent of individuals affected by deformities of one or more claws, with marked variation in severity. Affected animals represented all age and sex classes. We then collected eight elk with abnormal or normal hooves, representing three herds, necropsied them and collected tissue and biological specimens from

—Sushan Han, DVM, PhD, DACVP, CSU VDL Pathologist and CSU Microbiology, Immunology and Pathology Assistant Professor, and Kristin Mansfield, DVM, Washington Department of Fish and Wildlife.

distal limbs. Limbs and all viscera were examined by radiology, gross dissection, histopathology, viral and bacterial culture and polymerase chain reaction, serology, and hepatic trace mineral concentration analysis, and feces were examined for parasite burden.

Results of laboratory tests were unremarkable indicating no primary underlying disease conditions. Grossly, deformed claws varied from intact, but abnormally long and curved, to sloughed or broken, with common severe sole abscesses. Histology of affected and normal claws identified acute and chronic laminitis in most cases, with negative culture of hooves for common hoof rot pathogens. Hepatic selenium and copper levels in all elk were severely deficient. Chronic laminitis likely has an important role in the pathogenesis of lameness and aberrant growth of hooves, and may be indicative of a nutritional etiology. Additionally, marked copper deficiency may affect hoof keratin integrity predisposing elk to sole abscesses and hoof deformities. ▲



## Advances in Parasitology

# Comparison of Two Centrifugal Fecal Flotation Techniques

Fecal flotations are still the mainstay of gastrointestinal parasite detection in small animal practice. Simple flotation techniques are popular over centrifugation due to their simplicity and perceived cost benefit. However, studies have shown centrifugation enhances detection of parasite eggs, cysts or oocysts. A recently introduced single-use, disposable device for centrifugal flotation uses a coring tool to obtain the sample, thus minimizing mess while maintaining centrifugation's benefits. We evaluated this new technique using 55 feline and 70 canine fecal samples in animals from an area of relatively low parasite prevalence.


All samples were mixed, split and processed using both the new technique (OT) and a modified double centrifugation technique (MDCF) using Sheather's sugar (sp.g.=1.27).

Samples were scored as positive if any parasite egg or cyst was detected. Eggs per gram were determined for all helminth eggs, while a qualitative system was used to score

—Juliette Carroll, BS, College of Veterinary Medicine student, and Lora R. Ballweber, DVM, MS, CSU VDL Parasitology Section Head

the relative intensity of *Giardia* cysts for all samples.

Overall, 25 of 70, or 35.7 percent, of canine and 16 of 50, or 32 percent, of feline fecal samples had one or more parasites present. When samples were simply scored as parasites detected or not detected, substantial agreement occurred between techniques; however, when compared with the MDCF, OT detected fewer positive samples (35 vs. 40) and fewer parasites (45 vs. 54). This discrepancy centered primarily around *Toxocara canis* (OT=8; MDCF=11) and *Toxocara cati* (OT=8; MDCF=10). These samples tended to have low egg counts, which may explain the differences. Discrepancies were also noted in the detection of *Giardia* cysts (OT=11; MDCF=15). *Taenia* eggs were detected by OT but not by MDCF on one sample. Increasing the flotation time for OT when using sugar, which is more viscous than salt solutions, may solve these differences in detection. ▲



—Brandy Nagamine, MS, CSU VDL Parasitology Technician, and Lora R. Ballweber, DVM, MS, CSU VDL Parasitology Section Head

## THE FIVE MOST COMMON PARASITOLOGY FAQS WE RECEIVE

**Q** I want to submit a sample for the *Cryptosporidium*/*Giardia* IFA. What do I need to submit and how?

**A** The ideal sample is 3 grams of fresh feces. Less can be submitted, especially for diarrhea cases, but can impact the results. If you have less than 1 gram, call us at (970) 297-1233. Seal in a sterile container and send overnight on ice, unless also testing for *T. foetus*. (See below.)

**Q** I need to get my bulls tested for *T. foetus*. How do I send the sample?

**A** Many states regulate *T. foetus* bull testing, so please confirm you know the conditions accepted by your state regarding culture, PCR, time-frames, and others. In general, preputial scrapings for culture and PCR should be submitted using the InPouch™ TF system. Colorado samples must reach the lab within 48 hours after collection for culture; within 72 hours for PCR. Lactated ringers solution can be used as a transport media when InPouch™ TF media is unavailable, but must then reach the lab within 24 hours of collection. **Do not refrigerate.** We discourage shipping samples for Saturday receipt, and **no samples are accepted on Sundays.** All culture-positive Colorado bovine samples are submitted for PCR species confirmation.

**Q** Which is the better test for detection of trichomonads in a cat, culture or PCR? How do I submit the sample?

**A** Culture will detect about 55 percent of infected cats; PCR, about 30 percent; and together, about 75 percent. Therefore, optimal diagnostics include both tests. Culture samples can be submitted directly or inoculated into an InPouch™ TF Feline pouch inoculated with 0.05 gram—about a peppercorn size. If submitting feces, 1 gram is preferred. Feces can be prevented from drying out, which decreases the ability to find the organisms, by mixing two parts feces with three parts normal saline. Ship overnight. **Do not refrigerate.** Samples submitted for PCR alone can be shipped overnight on ice.

**Q** I'm submitting a fecal screen sample (flotation, direct wet mount, and *Cryptosporidium*/*Giardia* IFA). What do you need?

**A** Six grams or more of fresh feces is optimal sent for overnight delivery. **Do not refrigerate**—it will destroy any *T. foetus* or *Giardia* trophozoites present. If you have less than 2 grams, call us at (970) 297-1233 to discuss options.

**Q** I have a tick, louse or bug I would like identified. How do I submit it for identification?

**A** The specimen can be submitted as is or preserved in 70 percent ethanol or isopropyl alcohol. If preserved in alcohol, please note alcohol shipping regulations for your mail carrier.

## QUESTIONS?

- Contact us at (970) 297-1233
- See our test schedule link at [dlab.colostate.edu/webdocs/services/20110608\\_Parasitology\\_TestSchedule.pdf](http://dlab.colostate.edu/webdocs/services/20110608_Parasitology_TestSchedule.pdf)



New CSU VDL team members include (above) Chad Frank, (from left) Seung Yoo, Elijah Edmondson, Dan Regan and Craig Miller.



### Get to Know the Laboratory

## New Members Join the Lab Team

**Seung Yoo** is originally from Los Angeles. He earned a master's degree in nutrition from the University of California Davis in 2004 and graduated with a dual master's of business administration and DVM from CSU in 2010. In 2011, he completed a rotating small animal internship at Michigan State. He joins the Microbiology, Immunology and Pathology Department as a postdoctoral fellow, and is interested in studying coagulation. In his free time, he enjoys spending time with his wife, Stephanie, two dogs and three cats. He also enjoys snowboarding, hiking and playing ice hockey.

**Elijah Edmondson** hails from the idyllic farm lands of the small southern town of Tifton, Ga. He attended the University of Georgia to major in cellular biology and minor in English literature, graduating magna cum laude. Following undergrad, Elijah remained at Georgia for veterinary school, graduating in 2011. Now in his first year of Colorado State's anatomic pathology residency, he will pursue a doctorate in cancer biology.

**Dan Regan**, new veterinary pathology resident in the Microbiology, Immunology and Pathology Department, was born in Jersey City, N.J. He spent the majority of his life in St. Simons Island, Ga., Cleveland and, most recently, Athens, Ga., where he received a bachelor's degree in biology and DVM from the University of Georgia. His areas of research interest during his veterinary training included immunohistochemistry and cytokines associated with diseases of autoimmunity. Since making the journey to Fort Collins at the end of June, he hopes to apply that interest in cytokines and the immune system to help determine their role in cancer metastasis. Dan and his wife live with two dogs,

two snakes and four cats. His hobbies include outdoor activities such as downhill skiing, hiking, backpacking and tennis, as well as playing guitar.

**Craig Miller** grew up in the smoldering heat of the Arizona desert, where he completed two years of undergraduate studies at Arizona State before moving to Fort Collins. He finished his remaining undergraduate studies in microbiology at CSU, where he was exposed to pathology through the study of mycobacterial pathogenesis under Randall Basaraba. Craig began vet school at Colorado State University in fall 2007 and became involved in many research projects involving highly pathogenic avian influenza virus, rhadinovirus and feline immunodeficiency virus pathogenesis. The latter work culminated in a publication regarding strain specific neuropathogenicity of FIV. Craig graduated from veterinary school in May 2011 and accepted a position in the combined anatomic pathology residency/doctoral program at CSU, where he is working on his first year of doctoral research in viral characterization of FIV in salivary tissues. He and his wife of 10 years have three boys, aged 7, 4, and 1.5.

**Chad Frank** joins the faculty at the CSU Veterinary Diagnostic Laboratory and Microbiology, Immunology and Pathology Department. A veterinary anatomic pathologist, he did his residency at Purdue University, received his DVM from Michigan State University and earned a bachelor's degree in microbiology and master's degree in anatomy and physiology from Colorado State. His special interests are infectious diseases of livestock and neuropathology. Originally from Wheat Ridge, Colo., he enjoys all outdoor activities, especially biking, hiking, snowboarding and wakeboarding. ▲

### EXTERNAL ADVISORY COMMITTEE

- Dr. Joan Bowen, Small Ruminant, Wellington
- Mr. Norm Brown, Equine, Wellington
- Dr. Keith Roehr, State Vet, Dept of Agric, Denver
- Mr. Terry Fankhauser, Executive Director, CCA, Arvada
- Dr. Mike Gotchey, Equine, Steamboat Springs
- Dr. Bob Davies, Wildlife, Colo. Dept of Wildlife, Denver
- Dr. Marv Hamann, Mixed Practice, Pueblo West
- Mr. Ed Hansen, Beef Cattle, Livermore
- Dr. Dean Hendrickson, Director CSU Veterinary Teaching Hospital, Fort Collins
- Dr. Ron Kollers, Small Animal, Fort Collins
- Dr. Elisabeth Lawaczek, Colo. Dept of Public Health and Environment Denver
- Dr. Larry Mackey, Large Animal, Greeley
- Dr. Leesa McCue, Mixed Animal, Limon
- Dr. Del Miles, Beef Cattle, Greeley
- Dr. Mike Miller, Wildlife, Colorado Dept of Wildlife, Fort Collins
- Dr. Roger Perkins, USDA/AVIC/APHIS, Lakewood
- Mr. Kenny Rogers, CCA, Yuma
- Dr. Steve Wheeler, Small Animal, Englewood
- Dr. Lou Swanson, CSU Extension, Fort Collins
- Dr. Paul Lunn, CSU Clinical Sciences Department head, Fort Collins

CSU VDL In Press

## A Roundup of VDL Faculty Research

**Gingrich EN, Kurt T, Hyatt DR, Lappin MR, Ruch-Gallie R. Prevalence of methicillin-resistant staphylococci in northern Colorado shelter animals. *J Vet Diagn Invest.* 2011 Sep;23(5):947-50.**

Methicillin-resistant *Staphylococcus aureus* (MRSA) and *Staphylococcus pseudintermedius* (MRSP) have been recognized as significant pathogens in veterinary medicine. There have been documented cases of MRSA infection and colonization in veterinary critical care units, in veterinary personnel, and in equine and feline patients. To date, there have been no studies examining the prevalence of MRSA or MRSP colonization of cats and dogs in animal shelters in the United States. The purpose of the current study was to determine the prevalence of MRSA and MRSP in cats and dogs in a northern Colorado animal shelter.

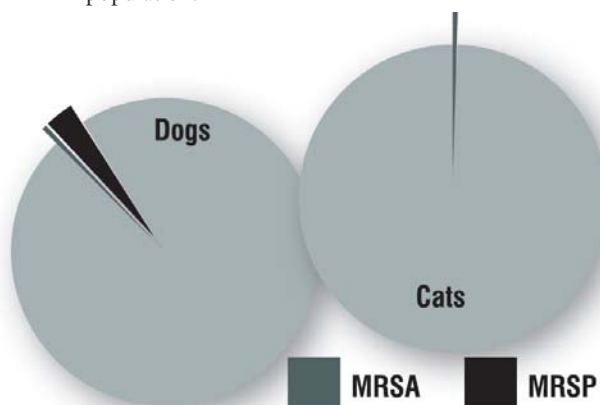
Samples were collected from 200 cats and 200 dogs in an open admission shelter. Each species was divided into 2 smaller groups: 100 dogs or cats housed in the stray ward and 100 dogs or cats housed in the adoption area. Samples were evaluated for the prevalence of MRSA or MRSP, which was verified through aerobic culture and Kirby-Bauer agar disc diffusion to confirm antimicrobial sensitivity. Results revealed MRSA in 0.5 percent of cat samples, MRSA in 0.5 percent of dog samples, and MRSP in 3 percent of dog samples. These results are consistent with previously published prevalence rates for these 2 organisms in non-shelter populations of dogs and cats, indicating that cats and dogs from this Colorado shelter do not appear to pose any greater risk to the public than do cats and dogs in the general pet population.



**Duncan C, Krafur G, Podell B, Baeten LA, Levan I, Charles B, Ehrhart EJ. Leptospirosis and Tularemia in Raccoons (*Procyon lotor*) of Larimer County, Colorado. *Zoonoses Public Health.* 2011 In Press.**

Raccoons (*Procyon lotor*) are commonly implicated as carriers of many zoonotic pathogens. The purpose of this cross-sectional study was to look for *Leptospira interrogans* and *Francisella tularensis* in opportunistically sampled, free-ranging raccoons of Larimer County, Colo. Sixty-five animals were included in the study and testing consisted of gross post-mortem examination, histopathology, and both immunohistochemistry and PCR for *L. interrogans* and *F. tularensis*.

No significant gross lesions were identified, and the most common histological lesions were lymphoplasmacytic interstitial nephritis and pulmonary silicosis; rare periportal hepatitis, splenic lymphoid hyperplasia and small pulmonary granulomas were also identified. Of 65 animals, 20 (30 percent) were positive for *Leptospira* on IHC but only one by PCR. Animals with inflammation in their kidneys were seven times more likely to be positive for *Leptospira* than animals without inflammation. The severity of inflammation was variable but often mild with minimal associated renal pathology. One animal was positive for *Francisella* on both IHC and PCR; IHC staining was localized to histiocytic cells within a pulmonary granuloma. In Colorado the significance and epidemiology of *Leptospira* is poorly understood. The high prevalence of infection in raccoons in this study population suggests that this



species may be important in the regional epidemiology or could be used to estimate risk to domestic animals and humans. Identification of a single *Francisella* positive animal is significant, as this is an uncommon disease in terrestrial animals within the state; the apparently higher prevalence in this peridomestic species implies that raccoons may be good indicators of the pathogen in the region. The results of this study suggest that raccoons may serve as effective sentinels for both *Leptospira* and *Francisella* in Colorado. Further studies are needed to better characterize the prevalence and epidemiology within the region.

**Slota KE, Hill AE, Keefe TJ, Bowen RA, Pabilonia KL. Biosecurity and bird movement practices in upland game bird facilities in the United States. *Avian Dis.* 2011 Jun;55(2):180-6.**

Since 1996, the emergence of Asian-origin highly pathogenic avian influenza subtype H5N1 has spurred great concern for the global poultry industry. In the United States, there is concern over the potential of a foreign avian disease incursion into the country. Noncommercial poultry operations, such as upland game bird facilities in the United States, may serve as a potential source of avian disease introduction to other bird populations including the commercial poultry industry, backyard flocks, or wildlife.

In order to evaluate how to prevent disease transmission from these facilities to other populations, we examined biosecurity practices and bird movement within the upland game bird industry in the United States. Persons that held a

current permit to keep, breed, or release upland game birds were surveyed for information on biosecurity practices, flock and release environments, and bird movement parameters. Biosecurity practices vary greatly among permit holders. Many facilities allow for interaction between wild birds and pen-reared birds, and there is regular long-distance movement of live adult birds among facilities. Results suggest that upland game bird facilities should be targeted for biosecurity education and disease surveillance efforts.



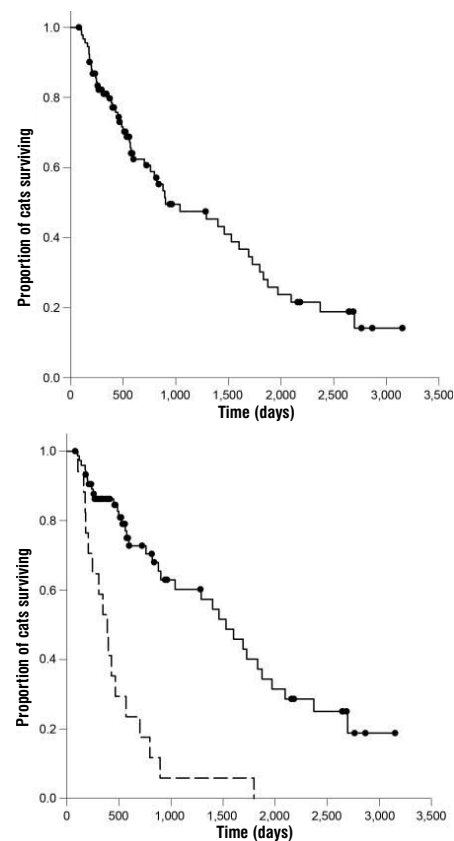
**Phelps HA, Kuntz CA, Milner RJ, Powers BE, Bacon NJ. Radical excision with five-centimeter margins for treatment of feline injection-site sarcomas: 91 cases (1998-2002). *J Am Vet Med Assoc.* 2011 Jul 1;239(1):97-106.**

This study aimed at evaluating the outcomes of radical excision of feline injection-site sarcomas (ISS) via assessment of local recurrence and metastasis rates, survival times, and complications associated with surgery.

The retrospective case series involved 91 cats with ISS. Medical records of cats that had radical excision of ISS without adjunctive treatment were reviewed. Information extracted included sex, type of surgical procedure, histologic tumor grade, tumor diameter, time from tumor detection to definitive surgery, complications associated with surgery, whether tumors recurred locally or metastasized, and survival times. Diagnosis of ISS was histologically confirmed, and additional follow-up was performed.

Results demonstrated that overall median survival time was 901 days. Thirteen of 91 (14 percent) cats had local tumor recurrence; 18 (20 percent) cats had evidence of metastasis after surgery. Median survival time of cats with and without recurrence was 499 and 1,461 days, respectively. Median survival time of cats with and without metastasis was 388 and 1,528 days, respectively. Tumor recurrence and metastasis were significantly associated with survival time; whereas, other examined variables were not. Major complications occurred in 10 cats, including seven with incisional dehiscence.

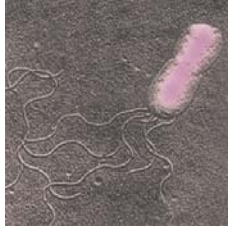The study suggests radical excision of ISS resulted in a metastasis rate similar to rates reported previously; the local recurrence rate appeared to be substantially less than rates reported after less aggressive surgeries, with or without adjuvant treatment. Major complication rates were similar to rates reported previously after aggressive surgical resection of ISS. Radical excision may be a valuable means of attaining an improved outcome in the treatment of feline ISS.



Gehan-Breslow curves for overall survival time (top) and survival time for those that did or didn't have local tumor recurrence after radical excision (bottom), showed different survival for the two groups. Median survival time for cats with local tumor recurrence was 499 days; 1,461 days for those without.

**Fenimore A, Varanat M, Maggi R, Schultheiss P, Breitschwerdt E, Lappin MR. Bartonella spp. DNA in cardiac tissues from dogs in Colorado and Wyoming. *J Vet Intern Med.* 2011 May-Jun;25(3):613-6.**

Photo: A.J. Conry/Flickr. Used by permission.



Because several *Bartonella* species have been identified in dogs diagnosed with infectious endocarditis (IE) or myocarditis, we evaluated cardiac tissues of nine dogs with suspected IE from January 1990 to June 2008 for the presence of *Bartonella* DNA.

In this retrospective study, medical records at the Veterinary Teaching Hospital were searched. Animals were excluded if there was no diagnosis of IE in the original necropsy report. Paraffin embedded tissue blocks and medical records were available from nine dogs. Total DNA was extracted from the cardiac tissues and assessed for *Bartonella* spp. DNA by three

polymerase chain reaction (PCR) methods. For positive samples, the *Bartonella* spp. were determined by genetic sequencing or fluorogenic real-time PCR.

*Bartonella henselae* DNA was amplified from the tissues of seven dogs; *Bartonella vinsonii* berkhoffii DNA was amplified concurrently from three dogs. Six dogs were from Colorado and one was from Wyoming. Flea or tick infestations were reported in two dogs.

Our results suggest *Bartonella* spp. should be on the differential list for dogs in the Rocky Mountain states. Of the seven dogs that tested positive for *Bartonella* spp. DNA, all had presented to CSU VTH with nonspecific clinical signs. Routine blood cultures were performed only on the two dogs with fever and heart murmurs, and none had been prospectively assessed for *Bartonella* spp. infection by PCR or culture. The results also emphasize the need for routine use of external parasite control products, even in low-risk regions. ▲

Canine Oncology Retrospective

# Clinical Outcome of Dogs Two Years After Mast Cell Tumor Removal

**THANKS TO OUR PARTNERS IN RESEARCH**

The authors wish to express their gratitude to the 109 veterinary clients of the CSU Veterinary Diagnostic Laboratory who provided information regarding clinical history, outcome, additional treatments, and animal breed, age and location of the cMCT.

This retrospective study of 100 dogs evaluated the relationship between width and depth of surgical margins, the amount of edema within and around the tumor and the degree of demarcation between the tumor and surrounding tissue with the clinical outcome of cutaneous mast cell tumors (cMCTs) in dogs.

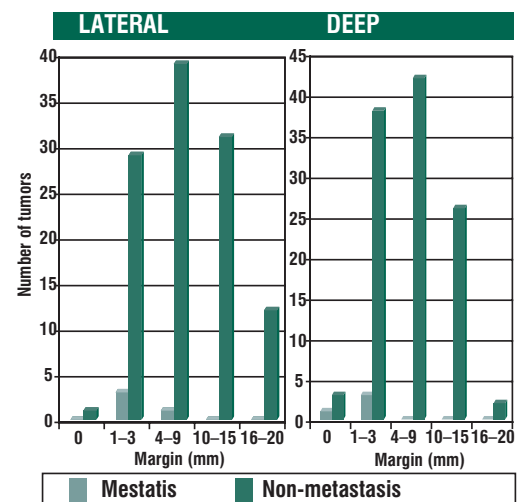
We obtained information about clinical outcomes of the 100 dogs with 115 resectable cutaneous mast cell tumors from veterinarians who are clients of CSU VDL. We then reviewed histologic sections of the tumors removed from the dogs.

Results showed that following surgical excision of the tumors, 96 dogs had no local recurrence or metastatic disease for 27 to 31 months, and four dogs had died of metastatic disease within three to nine months. The four tumors that led to metastatic disease included three grade III masses and one poorly differentiated grade II mass. None of the 100 dogs had received any therapy except the surgical excision.

In the histologic sections, the lateral surgical margins around the tumors averaged 8.9 mm (range 1 mm to more than 20 mm), and the deep margins averaged 5.3 mm (range 1 mm to more than 20 mm). No recurrence of tumor or metastatic disease developed with lateral margins of 10 mm or greater and deep margins of 4 mm or greater. Edema and degree of demarcation did not correlate with outcome.

— Patricia C. Schultheiss, DVM, PhD, DACVP, CSU VDL Pathologist; David W. Gardiner, DVM, DACVP, Idexx Laboratories; Sangeeta Rao, BVSc, MVSc, PhD, CSU Clinical Sciences Research Scientist; Francisco Olea-Popelka, DVM, MSc, PhD, CSU Clinical Sciences Assistant Professor; Joanne L. Tuohy, BA, North Carolina State University.

Results suggest most grade I and II cMCTs in dogs can be successfully treated by complete surgical removal with margins smaller than the 2 cm margins currently recommended. ▲



Schultheiss PC, Gardiner DW, Rao S, Olea-Popelka F, Tuohy JL. Association of histologic tumor characteristics and size of surgical margins with clinical outcome after surgical removal of cutaneous mast cell tumors in dogs. *J Am Vet Med Assoc.* 2011 Jun 1;238(11):1464-9.

## CSU VDL ON THE ROAD: UPCOMING CONFERENCES, SYMPOSIA AND APPEARANCES BY CSU VDL FACULTY MEMBERS

VDL Pathologist **Colleen Duncan** will present her work on *Coxiella burnetii* in northern fur seal placentas at the **Alaska Marine Science Symposium**, Jan. 16-20, in Anchorage.

**Barb Powers**, CSU VDL Director, **Jim Kennedy**, VDL Rocky Ford Branch Director, **Kristy Pabilonia**, Avian Diagnostics and BSL3 Operations Section Head, **Lora Ballweber**, VDL Parasitology Section Head, **Doreene Hyatt**, Bacteriology Section Head, **Dwayne Hamar**, Chemistry and Toxicology Section Head, VDL Microbiologist **Christina Weller**, VDL Pathologists **Terry Spraker**, **Tawfik Aboellail** and **Sushan Han**, and **Valerie Johnson** and **Joe Strecker** attended the annual meeting of the **American Association of Veterinary Laboratory Diagnosticians**, Sept. 29 through Oct. 5 in Buffalo, NY.

VDL Pathologist **EJ Ehrhart** will attend the **American College of Veterinary Pathologists** annual meeting Dec. 3 through 7 in Nashville.

**Barb Powers**, **Kristy Pabilonia**, **Lora Ballweber**, **Sushan Han** and **Jim Kennedy** attended the **Colorado Veterinary Medical Association** 2011 Convention, Sept. 15 to 18 in Keystone.

CSU VDL Assistant to the Director **James Kammerzell** will help organize the Bangkok conference "**Roadmap to LIMS**," Dec. 8 and 9, where he will discuss the build vs. buy of a LIMS and the use of open-source products.

**Kristy Pabilonia** conducted AAVLD audit requirements to ensure ongoing laboratory accreditation with the **American Association of Veterinary Laboratory Diagnosticians** the week of Nov 7 in Montreal. She will also be conducting research in Indonesia during December.

**Barb Powers** and **Kristy Pabilonia** attended the **CVMA's leadership conference** in Colorado Springs in October.

Look for **Barb Powers** at the **Colorado Cattlemens Association** mid-winter meeting in Denver, Jan. 17 and 18.

## Veterinary Outreach

# New ACVP Diplomates

### ANATOMIC PATHOLOGY

- Gopi Sivagiri Palanisamy  
*Postdoctoral fellowship, Memorial Sloan-Kettering Institute*
- Mona Bera  
*Postdoctoral fellowship, Harvard School of Medicine*
- Brendan Podell  
*Microbiology, Immunology and Pathology Fellowship Grant Trainee*
- Chuck Halsey  
*Microbiology, Immunology and Pathology Fellowship Grant Trainee*

### CLINICAL PATHOLOGY

- Davis Seelig  
*Microbiology, Immunology and Pathology Research Scientist/Scholar*
- Michael Wiseman  
*Clinical pathologist, ANTECH*

## WILDLIFE DISEASE ASSOCIATION HONORS VDL'S HIBLER FOR LIFETIME ACHIEVEMENT



Retired CSU VDL's Charles Hibler received the Wildlife Disease Association's Emeritus Award at the association's 60th Annual International Conference, Aug. 14-19, in Québec. The award is given annually in recognition of meritorious contributions to the study and understanding of diseases of wildlife.

A native of New Mexico, Hibler joined the CSU faculty in 1965, where he remained until retirement. At CSU, he has served as associate dean, professor and director of the Wild Animal Disease Center.

Dr. Hibler's parasitological research was varied, including many studies uncovering and elucidating elegant ecological relationships among vertebrates, invertebrate intermediate hosts and parasites. Much of the research of Hibler, his students and colleagues addressed practical wildlife management and human health problems relating to wildlife parasites and disease, including discoveries such as lungworm transplacentally transmitted in bighorn sheep, Johnes disease in bighorn sheep, chronic wasting disease in deer, waterborne giardiasis affecting domestic water supplies, and a protocol developed to protect water supplies. His research on *Elaeophora schneideri* in tabanids and mule deer and the impact of this system on sympatric wapiti was seminal. Editor of the *Journal of Wildlife Diseases* for seven years and former vice president of the association, he also received the group's distinguished service award in 1981.

## CONGRATULATIONS TO...

- Shannon McLeland; Microbiology, Immunology and Pathology veterinary resident; Winner of the CL Davis Student Scholarship Award.
- Valerie Johnson; Microbiology, Immunology and Pathology veterinary resident; winner of the American Association of Veterinary Laboratory Diagnosticians Trainee Travel Award, for the presentation of Johnson V, VanCampen H, Han S, Holmes K. Ferret Systemic Coronavirus Infection. In: Proceedings of the American Association of Veterinary Laboratory Diagnosticians 54th Annual Conference, September 28 - October 5, 2011; Buffalo, N.Y.; 2004:66.

**REGULAR COLUMNS**

- LAB UPDATE p. 1
- Director honored. p. 11
- LAB UPDATE p. 11
- Meet new staff members. p. 15
- OUTREACH p. 15
- New ACVP diplomates. p. 15
- OUTREACH p. 15
- Outreach recognized

**INSIDE THIS ISSUE**

**LAB LINES**

**PRODUCTION MEDICINE** . . . p. 2  
How to take a systematic approach to the complex question of abortion.

**E-SERVICES** . . . . . p. 5  
Need to clear your truck? Try some of the electronic services we now offer.

**PUBLIC HEALTH** . . . . . p. 6  
A case study that demonstrates the issues of lead toxicosis.



**STANDARDS CONSENSUS** p. 8  
Supporting the move toward consensus on interpreting gastrointestinal biopsies.

**PARASITOLOGY** . . . . . p. 10  
A comparison of two centrifugal fecal float techniques.

**VDL IN PRESS** . . . . . p. 12  
A roundup of recently published and in press work by VDL faculty members.



**LAB NEWS**

We recently returned from the American Association of Veterinary Laboratory Diagnosticians meeting in Buffalo, N.Y. It was a great pleasure to see many of you there. I was truly honored to receive the EP Pope Award. It is quite a humbling honor. It was also great to see many of you at the Fall Annual meeting of the Colorado Veterinary Medical Association. In January, we have our upcoming Annual Advisory Committee and we look forward to that meeting as we receive good advice on ways to move the laboratory forward.



**BARBARA POWERS, DVM, PHD, DACVP DIRECTOR**

# Update from the Director

Welcome to another issue of LabLines for the Fall and Winter, although it already appears to be winter in Colorado. In this issue, there is an abundant amount of information, as usual.

- First I would like to welcome our new residents who started July 1, and our new pathologist, Chad Frank, who started in October. Their addition to our team will finally bring pathology staffing up to the levels needed to meet growing demand.
- In this issue of LabLines, there is important information on a new panel for abortion diagnosis in small ruminants, as we approach the lambing and kidding season in late winter/early spring.
- We have had repeated requests for electronic certificates for EIA and trichomoniasis. Inside, you will find an article detailing this service, as well.
- Also, there is an example, again, of how veterinarians can participate in issues that may be related to public health as evidenced by the article on lead toxicosis. There are also numerous other articles that we hope are of interest to you.

As always, if you have any suggestions, please feel free to contact a member of the Advisory Committee or us for comments or ways to improve our service to you.

*Barbara E. Powers*



**PLEASE CONSIDER A YEAR-END CONTRIBUTION**

Your generous year-end donation to our foundation allows us to buy new or replace old equipment, perform in-depth disease investigations of unusual cases or enhance our ability to educate the next generation of veterinary laboratory diagnosticians. Visit [www.dlab.colostate.edu](http://www.dlab.colostate.edu)

Nonprofit Organization  
US Postage  
**PAID**  
Fort Collins, Colorado 80523  
Permit Number 19

**Colorado State University**  
Veterinary Diagnostic Laboratories  
College of Veterinary Medicine and Biomedical Sciences  
Fort Collins, CO 80523-1644